

X. *On the Development of the Vertebral Column of Urodela.*

By HIMADRI KUMAR MOOKERJEE, *M.Sc., D.I.C., Lecturer in Zoology, Sir Rash Behari Ghose Travelling Fellow, Calcutta University; Marshall Scholar, Imperial College of Science and Technology, London.*

(Communicated by Prof. E. W. MACBRIDE, *F.R.S.*)

(Received July 17, 1929—Read November 7, 1929—Revised March 5, 1930.)

[PLATES 44–48.]

CONTENTS.

	Page
Introduction	415
Material	416
Method	416
Method of rearing Urodela	416
Terminology	417
Observations of stages	417
Discussion	432
Summary	439
Literature	442
Explanation of figures	444

Introduction.

The justification of the following paper is found in the fact that notwithstanding the investigations of DUGES (1834), GEGENBAUR (1861, 1862, 1876), HASSE (1892), ZYKOFF (1893), GOEPPERT (1895), PETER (1895), GADOW (1896), KAPELKIN (1900), SCHAUINSLAND (1906) and EMELIANOFF (1925), which deal with the development of the vertebral column in Urodela, there still remains a great deal of uncertainty as to the relationship which exists, first, between the arches, the intervertebral and the vertebral bodies; secondly, as to the exact constituent parts of the neural and the hæmal arches; thirdly, as to whether any change takes place in the developing vertebra as it passes from its cartilaginous condition to its ossified stage, for none of the above-mentioned workers has traced the full development to the adult condition; fourthly, as to the development of the first (atlas) vertebra and its relation to the occipital region; lastly, as to how the Urodelan skull has developed two condyles for articulation with the first vertebra.

The writer desires to acknowledge his indebtedness to Prof. E. W. MACBRIDE, who, with valuable advice and criticism, has greatly facilitated these researches. He has also to acknowledge his obligations to Mr. H. R. HEWER, Mr. N. MURTI, Mr. P. GRAY, and Mr. C. JOHN for their kind assistance, which has led to the improvement of this paper.

Material.

The material for the development of *Triton vulgaris* was derived from specimens reared by the author himself, with the aid of Miss D. SLADDEN, in the Huxley Research Laboratory of the Imperial College of Science and Technology, London. The writer also wishes to take the opportunity of expressing his indebtedness to Miss SLADDEN in the rearing of the animals under artificial conditions.

Method.

Owing to the absence of any definite means of ascertaining the age of the animal, the writer has adopted the usual method of indicating age by size. It must, of course, be borne in mind that size can never be the sole factor in determining age, since there are individual variations in rapidity of growth.

Larvæ were measured from the tip of the snout to the end of the tail. The early embryonic stages of *Triton vulgaris* were fixed in Smith's fixative.* The larval and the post-larval stages were fixed in Bouin's fluid. The states of preservation were generally very satisfactory. Even for the early embryonic stages direct embedding in paraffin gave quite a good result. Generally the paraffin used in this investigation was of the melting point 56° C., but for the material fixed in Smith's fixative paraffin of 52° C. melting point was used.

To decalcify the advanced stages, 3 per cent. nitric acid with 70 per cent. alcohol was used for a number of days, according to the size of the specimen. The majority of the specimens were studied by means of serial, transverse, frontal and sagittal sections. For early embryonic stages Delafield's hæmatoxylin was used for staining the sections, they were differentiated afterwards with acid alcohol and then exposed to ammonia vapour in order to get rid of the last traces of acid. Mallory's triple stain and borax carmine, followed by picro-indigo-carmine, were used for larval as well as adult stages.

In order to compare the structure of a developing vertebra with its adult condition, in relation with other skeletal structures, the alizarine method† of staining the skeletal system was used. This was very useful especially for the vertebral column of *Triton vulgaris*, which is so very slender.

Method of Rearing Urodela.

White sand was kept in a glass tank, up to a height of 2 inches, after rinsing it in water to get rid of the various salts. A few stones and weeds were kept in the tank with 4 inches of water over the sand. At the beginning of spring the adult female newt was kept in the tank and she began to lay eggs one at a time on the leaves of the weed. These eggs were collected and transferred to another tank. The water was aerated all the time by means of an air pump, so that there might be an adequate supply of oxygen and the growth of bacteria prevented. It took about a month for the eggs to hatch. During this period different embryonic stages were fixed. Soon after

* 'Journ. Morph.,' vol. 23, p. 91 (1912).

† 'The Museums Journal,' vol. 28, No. 11, pp. 341-4 (May, 1929).

hatching the larvæ acquired their limbs, and the necessity of feeding them arose. The newts have a very striking peculiarity in their feeding habits ; unless the object of prey moves about they will not take it as food. For early larval stages *Daphnia* is the best food ; for post-larval stages and adults, cut pieces of slender earthworms are the best, but one has to move these earthworms to-and-fro by means of a pair of forceps before the snout of the animal, as otherwise it would not accept them as food. Periodically the water was changed in order to get rid of the contamination caused by the excretory matters as well as food particles.

Terminology.

GADOW introduced a series of terms for the different parts of a developing vertebra in his paper on Pisces ('Phil. Trans. Roy. Soc.,' London, 1895). In a subsequent paper ('Phil. Trans.,' 1896) he applied those terms in describing the Amphibians, and this is now recognised as the standard terminology. He, along with Miss ABBOT, compared these terms with those of other authors, so far as they thought the terms synonymous with their own. It is therefore needless to recapitulate the terminology of the previous authors.

Some of the parts of a developing vertebra were not known to GADOW, such as the *Dorsointervertebral* procartilaginous piece, which becomes divided into the zygapophyses. GADOW thought that the intervertebral cartilage was divided into two definite pieces, an interdorsal and an interventral ; but, as a matter of fact, no such division exists, the whole thing being one mass ; so that we have termed it the *intervertebral*.

GADOW did not observe the connective tissue arches. The upper cartilaginous arch has been described as *basidorsal* and the connective tissue arch as the *upper connective tissue arch*. Similarly the lower cartilaginous arch has been described as *basiventral*, and the connective tissue arch as the *lower connective tissue arch*.

Observations of Stages.

Stage A. (The embryo is almost spherical.)—This is the first stage in which we can see the distinct notochord. The neural folds on the two sides are wide apart. The neural canal is still a curved plate without dorsal protection. Ventral to the neural plate is the notochord on which the neural plate rests. In transverse section the notochord has a squarish shape (Plate 44, fig. 1). It is to be noted that there is no endoderm on the ventral side of the notochord as there is in *Anura*. The endodermal and mesodermal tissues are in contact with the notochord on two sides.

Stage B. (The embryo is curved ventrally.)—The notochord is round in transverse section. It has severed its connection with the mesodermal band. The anterior part of this band is already divided into somites, but its caudal portion is still undivided. The anterior somites have each acquired a cavity, called the *myocæle*. In longitudinal section the notochord is seen to consist of more than one row of cells (fig. 2). The neural folds of the two sides have united to form the spinal cord, which is still in contact with the notochord.

Stage C, 3 mm. (The embryo is slightly curved.)—A few vacuoles have appeared in the notochord. Outside the notochord an *elastic cuticular sheath* has appeared. The somites of the anterior region have budded off sclerotomic cells from their ventrolateral corners. The dorsal aorta is seen for the first time, ventral to the notochord. The caudal portion of the mesodermal band is now divided into somites but they have neither developed a myocoele nor do they proliferate sclerotomic cells like the anterior ones.

Stage D, 5 mm. (The embryo is almost straight.)—The notochord is very much vacuolated and only a few notochordal cells can be detected here and there. At the periphery of the notochord there is one layer of notochordal cells forming the *notochordal epithelium*, which has secreted a cuticular layer, the *elastic sheath*. Between this epithelial layer and the elastic sheath there is formed another fibrillar layer (*elastica interna* GADOW). The intersomitic septa are very distinct. After the liberation of sclerotomic cells the somites should be called *myotomes* and the septa between them *myosepta*. Corresponding to each anterior half of the myotome there is a spinal nerve ganglion. The cartilaginous auditory capsules are situated at the two antero-lateral sides of the notochord. Posterior to each auditory capsule is the vagus nerve ganglion.

Stage E, 7 mm. (The embryo is absolutely straight.)—The notochord is fully vacuolated. The sclerotomic cells liberated from each somite take on the form of a ring round the notochord called the *perichordal ring*, which corresponds to the middle of each myotome. The limit of each sclerotome is from one myoseptum to the next. This should be called the *primary segmentation* of the skeletogenous layer round the notochord. There are scattered sclerotomic cells round the spinal cord. Round the notochord there are some scattered spindle-shaped mesenchymatous cells which have not yet taken up any definite position.

Stage F, 8 mm.—In the anterior region of the notochord there are metamerial aggregations of sclerotomic cells above the dorsolateral corners of the notochord, the position of each of which corresponds to each posterior half of the myotome (fig. 3). The sclerotomic perichordal rings round the notochord have become extended both cranially and caudally. The posterior portion of the notochord has just acquired the sclerotomic perichordal rings but has as yet no dorsolateral aggregations of cells. At the hindermost end of the animal there are neither the spinal nerve ganglia nor the sclerotomic perichordal rings. The notochord is only surrounded by scattered sclerotomic cells.

Stage 10 mm.—A few of the most anterior of the dorsolateral aggregations of cells have become cartilaginous. These are the rudiments of the *basidorsals*. The mesenchymatous spindle-shaped cells which were disposed in a scattered manner have now taken up a definite position. They have filled up the interspaces between the consecutive sclerotomic perichordal rings and have also extended outside the sclerotomic perichordal rings. Thus we get a continuous tube outside the notochord, which should be called the *perichordal tube*. Even in the hindmost end of the notochord the perichordal rings have been formed and also the mesenchymatous spindle-shaped cells have filled up the interspaces between them.

In contrast to the previous stage, in which the notochord is of uniform diameter throughout, the present stage exhibits a notochord slightly moniliform in structure, and the perichordal tube has the same shape. The dilatations correspond to the middle of each myotome where there are perichordal rings, and the constrictions correspond to the intermyotomal regions where there are spindle-shaped mesenchymatous cells. These mesenchymatous spindle-shaped cells are almost in contact with the sheath of the notochord in the interperichordal (vertebral) region, and have extended in both cranial and caudal directions and partly envelope the perichordal rings. The basidorsals appear to exert pressure on the dorsolateral sides of the notochord between the successive perichordal rings. In the intermyotomal region of the most anterior segments there are some sclerotomic aggregations which are the beginnings of the posterior part of the ribs.

Stage G, 12 mm.—All the dorsolateral cellular aggregations have become cartilage in the trunk region. The fibrous mesenchymatous tissue alternating with the perichordal rings and also to some extent investing them, has become ossified. With the ossification of the mesenchymatous tissue the boundaries of the segments of the skeletogenous layer change; this is the *secondary segmentation*. We have seen that the primary segmentation of the skeletogenous layer outside the notochord corresponded to that of the myotomes. The spinal ganglion corresponds to the anterior half of each myotome and the basidorsal to its posterior half. With the onset of secondary segmentation the limit of a segment changes from being at the end of a myotome to the middle of a myotome. The ossified part of the skeletogenous layer outside the notochord has become transformed into a series of hour-glass-shaped double cones. The middle portion of the hour-glass is the *centrum* proper, which is very much constricted, but before and behind it are the thick perichordal rings; so that each new segment of the skeletogenous layer is formed by the union of the caudal half of one segment with the cranial half of the next primary segment.

Bearing this in mind, if we examine the auditory region of the skull we find that at the posterior limit of the auditory capsule there is the arch which corresponds to the caudal half of a myotome. Corresponding to the next myotome behind we get for its cranial half, the Vagus nerve ganglion; both these two taken together form one secondary segment. Corresponding to the caudal half of this vagus myotome we find the occipital arch. Corresponding to the cranial half of the myotome behind this there is a small nerve ganglion, and in addition another arch which is slightly deflected laterally. Corresponding to the caudal half of the next myotome behind this again we find the Atlas (first) arch proper. So that between the atlas (first) arch proper and the occipital arch there is an intercalated arch through which a spinal nerve passes (*nervus suboccipitalis*). The two pillars of this arch do not unite dorsally, but are deflected lateralwards and divide in a peculiar manner into two. There should be a ganglion between the atlas and the intercalated arch corresponding to the cranial half of the myotome, but this ganglion has disappeared.

After the chondrification of this arch element, connective tissue cells grow in from the sides, slanting forwards in a cranial direction, dividing the two bases of this arch into

two balls and two sockets. These connective tissue cells ultimately meet the sheath of the notochord from two sides, and then they continue outside the bony cone of the centrum towards the cranium and meet each other round its tip, enclosing between them the whole of the *intervertebral* cartilage between the occipital arch and the atlas centrum; so that in frontal section the path of the connective tissue cells has an inverted "U" shape. The cartilaginous cells of the occipital arch proper are quite different from the cartilaginous cells of the occipital condyles, which are the balls derived from the intercalated arch. Similarly the cups on the two sides which articulate with the occipital condyles, which are likewise pieces of the intercalated arch, have a different kind of cells from the atlas (first) arch proper (fig. 4).

The scattered sclerotomic cells, which surrounded the spinal cord in previous stages, have become aggregated at the dorsolateral corners of the notochord in each vertebral region of the trunk. A few notochordal cells, which were at the junction of the notochordal septa and also at the periphery in the previous stages, have become aggregated at the middle of the notochord in the vertebral region.

In contrast to the previous stage we note that the sclerotomic aggregation in the intermyotomal septum which is the distal end of the rib has become cartilaginous. The two ventrolateral sides of the notochord have two fibrous cellular masses applied to them which are the beginnings of the *basiventralia* of the trunk vertebræ. These masses are ventral to the vertebral artery. In the tail region the moniliform diameter of the notochord has just begun to be evident. The perichordal rings surround the dilated portions of the notochord and the fibrous mesenchymatous tissues surround its constricted portions. At the extreme end of the tail the spinal nerve ganglia and the perichordal rings can still be made out, but the fibrous mesenchymatous cells are disposed in a scattered manner.

Stage H, 15 mm.—The atlas (first) vertebra has more than one pair of dorsal arcualia, viz., the atlas (first) arch proper which is now cartilaginous. In front of this there is another small archlike structure slightly below the level of the atlas (first) arch proper. This small piece of arch is derived from the intercalated arch between the occipital arch proper and the atlas (first) arch proper, and part of it will fuse with the atlas (first) arch proper, forming the cups of the atlas (first) vertebra. These cups are projected laterally, so that in this stage of development there is an indication of lateral projections from the atlas (first) arch proper (fig. 5).

The occipital arch can be seen very clearly and can be differentiated from the occipital condyle, which is composed of quite different kind of cells. The connective tissue cells, which in the previous stage grew between the occipital arch proper and the atlas (first) arch proper, have been split into two layers. As a result of the split a cavity is formed between the two layers of the connective tissue, which is the *synovial cavity* between the occipital condyle and the cup on the atlas (first) vertebra. The connective tissue cells are on the surfaces of the occipital condyles as well as on the surfaces of the sockets of the atlas (first) arch, which are now in a procartilaginous state. The nerve *sub-*

occipitalis can be seen distinctly in the region of the cup portion of the atlas arch. The sclerotomic perichordal rings round the notochord corresponding to the middle of each myotome are now in cartilaginous condition.

The trunk vertebræ have still cartilaginous basidorsals, but the basidorsal of one side does not meet and fuse directly with that on the other side. Between the two basidorsals in the mid-dorsal region there is a mass of sclerotomic connective tissue cells which bridges the gap between them. On the outer lateral aspect of each basidorsal cartilage of the second, third and fourth vertebra there are sclerotomic cell aggregations, which will ultimately form the *rib-bearing processes*. On the two ventrolateral sides of the notochord in the trunk region in each sequence there are two ossified thin bands, which were in a fibrous condition in the previous stage and which extend outwards and come into connection with the rib-bearing processes at their outer ends; these may be termed the *parapophyses*.

Between the two consecutive cartilaginous arches in the intervertebral region there are aggregations of sclerotomic cells at the dorsolateral corners. The myotomes of two sides do not unite mid-dorsally, but they are in contact with these sclerotomic aggregations on two sides, so that these look like the continuation of the myotomes. These aggregations of sclerotomic cells are continued in a slanting manner, craniocaudally, so as to join the supradorsal cartilage on one vertebra with the anterior connective tissue arch (*v. infra*) of the next vertebra. This is to be called the *Dorsointervertebral*. The dorsointervertebral is responsible for the formation of the *zygapophyses* of the vertebra.

Between the two consecutive cartilaginous arches there is fibrous tissue filling up the interspaces. This fibrous tissue is continuous from right to left above the spinal cord. It forms pillars in front of and behind the basidorsal which are joined above by a connective tissue roof, which has lateral projections at its two sides. The sclerotomic dorsointervertebrals are situated at the dorsolateral corners of these connective tissue pillars. The spinal nerve ganglia are on two lateral aspects of them (fig. 6). These pillars when ossified are what we term the *anterior and posterior upper connective tissue arches*.

The *intravertebral* notochordal cells have become aggregated much more markedly than in the previous stage. The posterior portions of the ribs, which are now distinct cartilaginous structures lying within the intermyotomial septa of the trunk region, have acquired sclerotomic connections with the sclerotomic rib-bearing processes of the second, third and fourth vertebræ.

In the tail region in this stage there are dorsolateral aggregations of sclerotomic cells between successive perichordal rings. The fibrous mesenchymatous cells surrounding the interspaces between the perichordal rings have constricted the notochord, and also the dorsolateral aggregations help them to constrict the notochord at the dorsolateral corners. There are numerous scattered sclerotomic cells ventral to the notochord, without a definite arrangement, surrounding the blood vessels.

At the extreme end of the tail, the fibrous mesenchymatous tissue cells have taken up a definite position. They have occupied the interspaces of the perichordal rings round

the notochord. They not only occupy the interspaces of the perichordal rings but also project over the perichordal rings slightly at their two extremities.

Stage I, 20 mm.—Occipital condyles can be clearly differentiated from the cartilaginous cells of the occipital arch proper and the cups of the atlas (first) vertebra also exhibit a clear differentiation from the cartilaginous atlas (first) arch proper. The cartilage of the occipital condyles and of the cups of the atlas exhibit an identical arrangement of cells. We can identify these structures more precisely from the peculiarity of the second vertebral arch. The atlas (first) arch is followed by the second vertebra, which carries a rib-bearing process. The nerve *sub-occipitalis* (= spinalis I) can be easily seen coming out through the cup of the atlas, and between the atlas (first) arch and the second vertebral arch there is the nerve spinalis II (fig. 7), which is the hypoglossal nerve.

The cartilaginous dorsal arcualia slant backwards and in the trunk the dorsal arcualia which were not complete in previous stages now enclose completely the spinal cord. The basidorsals of the two sides do not however meet, but between them dorsally is interposed a third piece of cartilage, which is of independent origin. This piece we shall term *supradorsal* (fig. 8). It is situated slightly posterior to the basidorsals, which therefore in their anterior portions are merely connected above by fibrous tissue. The cartilaginous cells, and especially the arrangement of their nuclei of the “supradorsal,” are quite different from the cells of the basidorsal or their nuclei.

In a para-sagittal section in which we find the basidorsal (dorsal arcualia) we cannot find the connective tissue arches, because they are not in the same plane. The basidorsal arch is very much curved, but the connective tissue arch is almost at right-angles to the body of the vertebra. The dorso-intervertebral mass of mesenchyme is now in a procartilaginous state and there are connective tissue cells migrating to this horizontally. These connective tissue cells split up into two layers along the line of their migration, so that the space between them goes to form the synovial cavity (fig. 9).

The rib-bearing processes of the second, third and fourth vertebræ are now in a procartilaginous state. The proximal portions of the ribs, in the cases of second, third and fourth vertebræ, are still in a membranous condition. In contrast to the previous stage there are now sclerotomic cell aggregations on the outer sides of the basidorsals in almost all the trunk vertebræ. Another aggregation is formed *ventral to the vertebral artery* which eventually attaches the rib to the centrum.*

Behind the union of the dorsal arcualia the supradorsal cartilage projects backwards, and where anteriorly the basidorsals flank the sides of the spinal cord there are the

* According to a paper by Mr. P. GRAY, B.Sc., now in the press ('Proc. Zool. Soc. Lond.,' 1930), "On the attachment of the Urodele rib to the centrum," Mr. MOOKERJEE is not quite correct in this statement. The attachment of the rib to the centrum in Triton, according to Mr. GRAY, is effected as in Amniota by the growth of the rib inwards beneath the vertebral artery until it reaches the centrum. This attachment therefore is exactly homologous with the capitulum or head of the rib. The rib-bearer (diapophysis) joins, however, not only the dorsal fork of the rib (tubercle) but also establishes secondarily an osseous attachment with the neck of the capitulum above the vertebral artery. This has been mistaken by previous authors for the true capitulum.—E.W.M.

procartilaginous dorsointervertebral bodies, which will form zygapophyses. A strand of connective tissue cells is growing into the procartilaginous dorsointervertebral bar, in a horizontal plane, so that the end of this bar joining the supradorsal is at higher level than the end joining the basidorsals of the next vertebra. The portions of the dorsointervertebral which are at a higher level, forming the lateral portions of the supradorsal, are the *post-zygapophyses*, and those which are at a lower level are the *pre-zygapophyses*.

The growth of the intervertebral (perichordal) cartilage rings of the trunk vertebræ has increased and these slightly constrict the notochord ; so that the dilated notochord in the intervertebral region has diminished and has the same diameter as that of the constricted vertebral portions.

In the tail region the dorsolateral aggregations of a few anterior vertebræ are in procartilaginous state. There is another aggregation of sclerotomic cells on the ventrolateral corners of the notochord of these anterior vertebræ of the tail region. These ventrolateral aggregations of sclerotomic cells are slightly inclined backwards. Between the bases of the ventrolateral sclerotomic mesenchymatous masses is situated the caudal artery (fig. 10).

Stage J, 25 mm.—Through the cup portion of the intercalated arch adhering to the atlas, in front, the nerve sub-occipitalis can be clearly seen (fig. 11). Posterior to the atlas (first) arch we get corresponding to the cranial half of the myotome a spinal nerve ganglion and corresponding to the caudal half the second arch.

In frontal sections through the occipital region we discover the occipital arch followed by the ball and the socket, and between the ball and the socket there are the connective tissue cells which grew in the previous stage ; these are now in a cartilaginous condition and are divided into two layers. Between the ball and socket on the right side and those on the left there is new cartilaginous tissue in the shape of a “U” with arms turned backwards. The base of the “U” is the so-called odontoid process of the Urodela. This base consists of cartilage *inside* the bony cone of the centrum and must, therefore, be regarded as homologous with the intervertebral cartilage found between successive centre (fig. 12). A section passing dorsally to the previous one shows the relative positions of the arches and the ball and socket, as well as the exit of the nerve sub-occipitalis through the cup portion of the atlas (first) arch (fig. 13).

The cartilaginous cells of the trunk basidorsals together with the inner perichondrial layer now degenerate (fig. 14). This section shows the anterior end of the dorsal arcualia, where there is no supradorsal element but where the basidorsal of one side is connected with the basidorsal of the other by means of an osseous band, which was developed from fibrous mesenchymatous tissue, like the connective tissue arch pillars which intervene between the two consecutive basidorsals. This osseous roofing is peculiar in that it has a lateral projection on both sides. The procartilaginous rib-bearing processes on the dorsolateral arcualia of the second, third and fourth vertebræ of the trunk region are now cartilaginous. Between the centrum and the rib-bearing process (diapophysis)

on two sides the vertebral artery can be clearly identified. There are the remnants of the inner perichondrial layer at the base of each basidorsal. The pillars of the anterior connective tissue arch are joined above by a roof of connective tissue, from the middle of which there projects upwards a fibrous projection which gives rise to the *neural spine*.

This outer perichondrial layer now becomes ossified and the ossification spreads into the connective tissue arches between the two consecutive pairs of dorsal arcualia, but the portion of each arch just near the zygapophyses remains fibrous without undergoing ossification, so as to permit the movement of one vertebra on another.

In contrast to the previous stages the notochord has again changed its shape. After the ossification of the mesenchymatous tissue which filled up the interspaces of the perichordal rings of the perichordal tube, the region of growth of the perichordal tube changes from a vertebral to an intervertebral zone, and here the cartilaginous ring increases in bulk and constricts the notochord in the intervertebral region; so that the original dilatations of the notochord in the intervertebral region become more constricted than the constricted portion of the vertebral region. Thus we get the reversion of the moniliformity of the notochord (fig. 15). Each end of the hour-glass-like bony centrum overlaps the intervertebral cartilage, but the overlap of one centrum does not reach the overlap of the next. Between them grows in a tongue of connective tissue, slanting towards the head, which cuts the intervertebral cartilage into two pieces, viz., a concave piece in front and a convex piece behind. These connective tissue cells can clearly be differentiated from the cartilaginous cells of the perichordal (intervertebral) ring.

The strands of connective tissue which penetrated into the procartilaginous dorso-intervertebral bodies in the previous stage have split up into two, with a cavity inside them. This cavity is the synovial cavity. The dorsointervertebral bodies are clearly divided into two, the pre- and the post-zygapophyses. The pre- and the post-zygapophyses are now cartilaginous and the connective tissue cells at the edges of the synovial cavity are in a procartilaginous state.

The ribs, which were in mesenchymatous condition at their proximal ends where they were articulated with a rib-bearing process, have become procartilaginous. The neural arches of the tail vertebræ are just like the neural arches of the trunk vertebræ.

In the posterior portion of the tail there are a few cartilaginous basiventral arches. These arches are not completed ventrally by cartilaginous structures so as to enclose the blood-vessels. There is a median aggregation of sclerotomic cells, which connects the basiventral of one side with the basiventral of the other; this should be called the *infraventral*. The ventral arcualia are slightly inclined posteriorly. On the two sides of the basiventral cartilages there are two sclerotomic cell aggregations, which are projections near the base of the basiventral and have a tendency to bend upwards. These are the *parapophyses*.

The rest of the tail region has sclerotomic arches at the dorsolateral corners of the notochord in the vertebral regions. The fibrous mesenchymatous tissue filling up the interspaces of the perichordal rings of the anterior portion of the tail becomes osseous,

and has an hour-glass form; this is the centrum. The perichordal rings are also changed into cartilage. As the fibrous mesenchymatous tissue also partly envelopes the perichordal ring there is a little space left by the two consecutive hour-glass shaped osseous structures. The moniliform shape of the notochord is very prominent here, the dilatations are confined to the intervertebral region (perichordal ring) and the constrictions to the vertebral (interspaces of the perichordal rings). There are a few notochordal cells aggregated in the middle of the vertebral region. The posterior portion of the tail has still the fibrous mesenchymatous tissue cells filling up the interspaces between sclerotomic perichordal rings. Here the moniliform shape of the notochord is not very distinct.

Stage K, 35 mm.—The cartilaginous cells of the occipital arch and the cartilaginous cells of the occipital condyles are now in a mature condition and are difficult to distinguish one from the other; so also are the cartilaginous cells of the cups of the atlas (first) vertebra and the rest of the atlas (first) arch. Only the cartilage cells of the edges of the condyles, as well as the edges of the cups, are quite different. These originated from the connective tissue which cut into the odd piece of arch from which the condyles and the sockets were formed.

If we go through the serial transverse sections of a trunk vertebra we shall find first just a little bit of the post-zygapophysis of the vertebra in front articulating with the pre-zygapophysis of the vertebra in question. The connective tissue arch, which forms the anterior portion of the vertebra, is clearly seen to be ossified (fig. 16). The roofing of the arch is also ossified and is identical in character with the side pillars of the arch. Outside the notochordal sheath there is the intervertebral cartilage, which has constricted the notochord to a great extent. Outside this intervertebral cartilage there is the osseous layer of the projecting end hour-glass shaped centrum of the vertebra.

In a few sections posterior to this we encounter the connective tissue arch ossified. The connective tissue arch has two vertical sides, with a third piece as roof, which has two lateral projections (see text-fig. 2, p. 431). These projections are responsible for the formation of the shelf-like structures found in the adult vertebra. The roof has a dorsal projection just at the middle point, which is also osseous; this middle projection is the neural spine. There is also a vestigial trace of an osseous basiventral element. Between the downwardly projecting vertical pillars of the connective tissue arch which are the diapophyses and the osseous basiventral lies the vertebral artery. On the left-hand side of the figure there is seen the union of the diapophysis with the parapophysis of the basiventral. Outside the notochord there is the thin intervertebral cartilage, but as the sections approach the waist of the hour-glass or the middle of the centrum there is no cartilage at all outside the notochordal sheath (fig. 17). The rib which in the previous stage was connected to the centrum by connective tissue is now joined to it by an osseous rod which is below the vertebral artery.

Further backwards we encounter the degenerated basidorsals with little projections of the inner perichondrial layer at the bases. On the two lateral aspects of the degenerated

basidorsal elements there are the cartilaginous rib-bearing processes, and also a trace of the proximal portion of the rib. As the dorsal arcualia are bent backwards we cannot get the whole of the dorsal arcualia in the same section. The roofing of this region is completed by the connective tissue arch, with two lateral projections, and a median dorsal projection which is the neural spine. All these structures are now ossified. The notochord has no cartilaginous cells outside the sheath, because this section passes through the waist of the hour-glass shaped centrum, where there is no trace of intervertebral cartilage, but the notochordal cells which were aggregated in the vertebral region are now transformed into cartilage. These cartilaginous cells are called, according to their position, *intravertebral* cartilage, and this is the only known instance of notochordal cells being converted into cartilage (fig. 18). A few sections after this we get the supradorsal as a huge cartilage.

We should remember that the cartilaginous cells of the dorsal arcualia have degenerated, except those of the supradorsal, and now with growth this has become a massive structure. On its two lateral aspects we get the post-zygapophyses. There is a good deal of difference between the cartilaginous cells of the supradorsal and the cartilaginous cells of the post-zygapophyses, because the latter have developed much later than the former. At the edge of the post-zygapophyses there are some new cartilaginous cells, quite distinct from the post-zygapophyses proper. These are the cells derived from the connective tissue cells, which migrated inside in order to divide the dorsointervertebral body into pre- and post-zygapophyses. Articulating with the post-zygapophysis we get the pre-zygapophysis of the next vertebra. Below the pre-zygapophysis we get the connective tissue roof (now ossified) of the next vertebra.

This section passes through the junction of the two vertebræ and we get the fibrous layers on the two sides of the spinal cord, the existence of which in previous stages has been already mentioned, when part of the connective tissue arch remained as fibrous connective tissue at the junction of the two vertebræ and the remaining portions of this arch became ossified. To prove that this is the junction of two vertebræ we have the articulation of the zygapophyses and also the ball and the socket portion of the former intervertebral cartilage. The notochord is very much reduced owing to the fact that the ball portion of the intervertebral cartilage has constricted it. Outside the cartilaginous mass of the ball we get the socket which is in osseous condition and there is a continuous cavity, the synovial cavity, between the ball and the socket.

The supradorsal element is in the posterior limit of a vertebra and does not carry a spine. The spine originates from the connective tissue arch element, and not from the dorsal arcualia. At the base of the fibrous connective tissue element there are on two lateral aspects of the notochord the vertebral arteries (fig. 19).

If we go through a series of frontal sections through a trunk vertebra, we shall encounter first the osseous neural spine at the anterior region of the vertebra, and at the posterior region the supradorsal cartilage. A section below this level shows the spinal cord in the middle. In the intermyotomal region there are two cavities which were

occupied by the cartilaginous basidorsals now degenerated. The two lateral cartilaginous projections from these are the post-zygapophyses. The post-zygapophyses are seen to articulate with a little bit of the pre-zygapophyses of the next vertebra. There are parallel osseous bars both at the anterior and the posterior ends of the degenerated basidorsals. These osseous rod-like structures are the connective tissue arches. At the junction of the rod-like osseous bar with the zygapophyses we can see just a break and the slightly diverging element of the bar. These are the fibrous layers of the connective tissue arch at the junctions of the pre- and the post-zygapophyses (fig. 20).

A frontal section through the body of the vertebra shows the intervertebral articulation. The connective tissue cells which grow in a slanting manner in a caudal to cranial direction are now in a procartilagenous state. These cells can be easily differentiated from the cartilaginous cells of the intervertebral body. The procartilagenous cells formed from connective tissue cells have not yet split up into two so as to divide the intervertebral cartilage into ball and socket, as will ultimately take place.

The intervertebral cartilage is outside the notochordal sheath and its position is in the centre of a myotome. The centrum proper is the intermyotomal region, and within the notochordal sheath in the middle portion of the hour-glass shaped centrum we find the intravertebral cartilage, which developed from the notochordal cells. On the two sides of the centrum there are the rib-bearing processes with ribs and at the points of articulation of the ribs there are sutures.

That the vertebra is opisthocœlous can be definitely seen from the direction of the arc of the connective tissue, which will form the joint as well as the spinal nerve ganglia at the anterior half of the myotome, so that the cranium is towards the top (fig. 21).

Sagittal sections through the trunk vertebræ show the supradorsal cartilages slanting in antero-posterior direction. In front, as well as at the back, of this supradorsal cartilage there are osseous rods. These are the connective tissue arches which are now ossified. Below this there is the spinal cord. This section shows clearly the reversion of the moniliformity of the notochord. The original moniliformity was the dilated intervertebral regions and constricted vertebral regions. Now the reversed moniliformity is the dilated vertebral regions and the intervertebral cartilages. In the vertebral region within the notochordal tissue there is the trace of the intravertebral cartilage (fig. 22).

In the anterior tail vertebræ the supradorsal is cartilaginous; the two basidorsals of each arcualia have degenerated, just like the trunk vertebra, leaving only the outer perichondrial layer (fig. 23). The post-zygapophyses bodies are cartilaginous, and so also the pre-zygapophyses. The connective tissue arches in front, as well as at the back, of the dorsal arcualia are now osseous. From the middle point of the roof of connective tissue arches there are osseous projections, the neural spines.

The parapophyses have severed their connection with the basiventral and have pushed upwards, *i.e.*, they are at the middle portion of the vertebral centrum. They have partly degenerated, owing to the degeneration of their cartilaginous cells and also of their

inner perichondrial layer. A few anterior vertebræ of the tail region have now acquired cartilaginous infraventral bodies (fig. 24). Between the two consecutive ventral arcualia there is mesenchymatous connective tissue, like that in the dorsal region. The notochordal cells which aggregated in the middle of the vertebral region have changed into procartilage (the intravertebral cartilage).

The posterior vertebræ of the tail have osseous vertebral bodies and also the cartilaginous perichordal rings. Connective tissue cells are growing in a slanting manner caudal to cranialwards for the division of the perichordal (intervertebral) cartilage. In the vertebral region there are notochordal cell aggregations for the formation of the intravertebral cartilages. The dorsal arcualia are cartilaginous. The zygapophyses are also cartilaginous. The connective tissue arches anterior as well as posterior to the vertebra are in a fibrous mesenchymatous mass. The ventral arcualia are procartilaginous and the infraventral body is sclerotomic.

Stage L, 40 mm.—The supradorsal cartilage of the trunk vertebra is partially replaced by bone-marrow. The outer perichondrial layers of the basidorsals are osseous and have grown thicker, with a knob-like structure at their free ends. The rib-bearing cartilage is also partially replaced by bone-marrow. The intervertebral cartilage is completely divided into two parts, as the ball and the socket. Even these cartilaginous structures are also partially replaced by bone-marrow. The intravertebral cartilage is partially evacuated by bone-marrow. The rest of the rib-bearing processes are now mature cartilage, and also the whole of the rib.

The anterior portions of the tail vertebræ have cartilaginous supradorsals. The outer perichondrial layer of the basidorsals has become ossified. On the outer sides there are cartilaginous projections (diapophyses) directed downwards. The basiventral cartilages have also degenerated leaving the outer perichondrial layer to become bone, like the dorsal arcualia. The infraventral body retains its cartilage. On the two sides of the centrum there are cartilaginous projections directed upwards (parapophyses). The diapophyses and parapophyses meet near the middle region of the body of the vertebra. The connective tissue arches between two successive dorsal arcualia are ossified, except at the place of articulation of the ribs, where there is a fibrous mass present throughout life. The connective tissue intervening between successive ventral arcualia likewise becomes ossified when the outer perichondrial layer of the arches becomes ossified (fig. 25).

A sagittal section of the anterior vertebræ of the tail region shows the backwardly-directed supradorsal, in front, behind which there are the ossified connective tissue arches. Below this there is the spinal cord. The most constricted region of the notochord is changing from a vertebral to an invertebral position. As a result of this change we get the dilatations in the vertebral region and constrictions in the intervertebral regions, on account of the growth of the intervertebral cartilage.

Beneath the centrum we get the backwardly-directed infraventral cartilage, before and behind which are the osseous rods derived from the connective tissue arches

on two sides of the ventral arcualia. There are also traces of intravertebral cartilage (fig. 26).

The parapophysis which retains its connection with the basiventral has become ossified and is connected with the downward projected diapophyses of the neural arch. There is no rib in the tail region (fig. 27).

Stage M, 45 mm.—The supradorsal of the anterior region of the tail has been replaced partly by bone-marrow. The outer perichondrial layer of the basidorsals is osseous. The parapophyses are osseous. The hæmal ossified connective tissue arches have long ventral spines (hæmal spine). The intravertebral cartilages are in a mature condition. A remnant of the notochord still persists in the intervertebral region. The posterior portion of the tail has cartilaginous supradorsal as well as infraventral.

Stage N, 65 mm.—The occipital condyles are osseous and are no longer distinguishable from the occipital arch. They articulate with the cups of the atlas arch on two sides, and between them there is a bony piece projecting forward, the so-called *odontoid process*. The cups are somewhat deflected laterally, so that they are not in the same plane as that of the atlas (first) arch proper. There is quite a big gap between the cranium and the atlas (first) arch proper on the dorsal side, where the spinal cord is exposed, because of the slanting and incomplete nature of the cup portion of the arch of the atlas (first) vertebra.

In the trunk vertebra, if we go through a series of transverse sections, we will find at the posterior portion of the articulation of vertebræ, the prominent pre-zygapophyses and just a trace of post-zygapophyses. Both are still cartilaginous. Between them is the synovial cavity. Below the pre-zygapophyses we encounter the roofing of the connective tissue arch, which is now ossified and has grown thicker, with a middle dorsal projection, the neural spine. There is fibrous tissue on the two lateral aspects of the centrum connecting the zygapophyses with the centrum, for facilitating the movement of the vertebræ. Near the base of these fibrous masses and the centrum there are vertebral arteries. The cup portion of articular body is osseous, but the ball still retains some cartilaginous cells, which have an osseous outer layer (fig. 28).

A few sections posterior to this, the post-zygapophyses, on two sides have almost disappeared. As a continuation of the anterior zygapophyses we get the projections of the roofing of the connective tissue arch, which is now osseous. The neural spine is thicker than before. As it approaches towards the vertebral region the centrum is almost evacuated by bone-marrow, so that hardly any trace is left of either cartilage or notochord (fig. 29).

A section posterior to the above shows that there are osseous outer perichondrial layers of the basidorsals which are thickened slightly with the growth of the animal. There are rib-bearing processes (diapophyses) on two lateral aspects of it which have been hollowed out by a mass of bone-marrow. There are the vertebral arteries on each side of the centrum. The centrum is also evacuated by bone-marrow. The basidorsals in this region are roofed by connective tissue as this section is just

anterior to the region of the supradorsal element. In the middle of this roof is the neural spine (fig. 30).

Caudal to this region the section shows that the supradorsal element, which retained its cartilages till the previous stage, has now been evacuated by bone-marrow ; it is quite a massive structure. On the two lateral sides of the supradorsal there are the osseous connections with the cartilaginous post-zygapophyses. Ventral to these post-zygapophyses are the synovial cavities. Below this there are just traces of the pre-zygapophyses. Connecting the pre-zygapophyses there are partly the traces of fibrous connective tissues and partly connective tissue arches, which are now osseous. Within the notochord there are the cartilaginous cells of the intravertebral element. The spinal nerves can be found, penetrating through the connective tissue arches, which are now osseous. Outside the arch on two lateral sides are the spinal nerve ganglia. On the two lateral aspects of the arch and the centrum there are cut ends of the tuberculum and the so-called capitulum of the ribs (fig. 31).

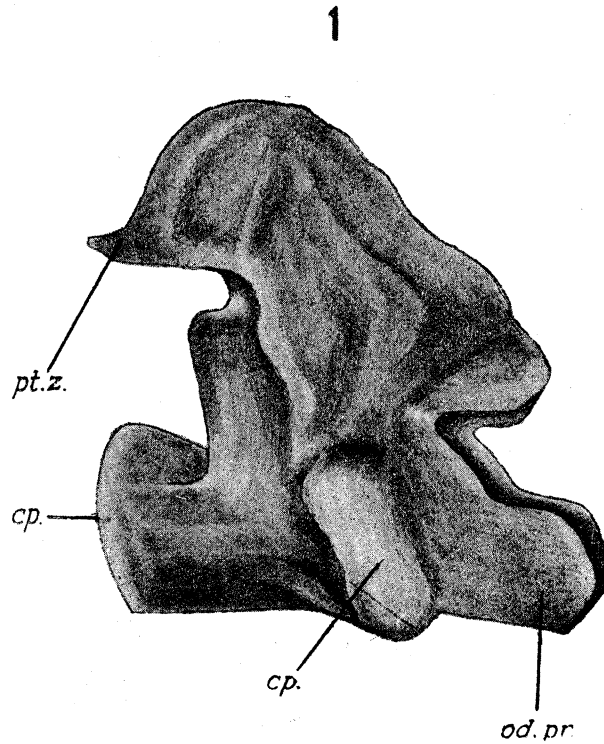
The next section shows the extreme limit of a vertebra. On the dorsal side there is the massive supradorsal with the cartilaginous dorsolateral. Below the supradorsal in the middle region is a trace of the roof of connective tissue arch of the next vertebra. Articulating with the post-zygapophyses are the pre-zygapophyses of the next vertebra. On the two dorsolateral sides of the centrum there are fibrous connective tissue cells. There are cartilaginous cells within the osseous ring of the intervertebral element, which is the ball, and the outer ring is the socket (fig. 32).

The Adult Atlas (first) Vertebra. (Text-fig. 1.)

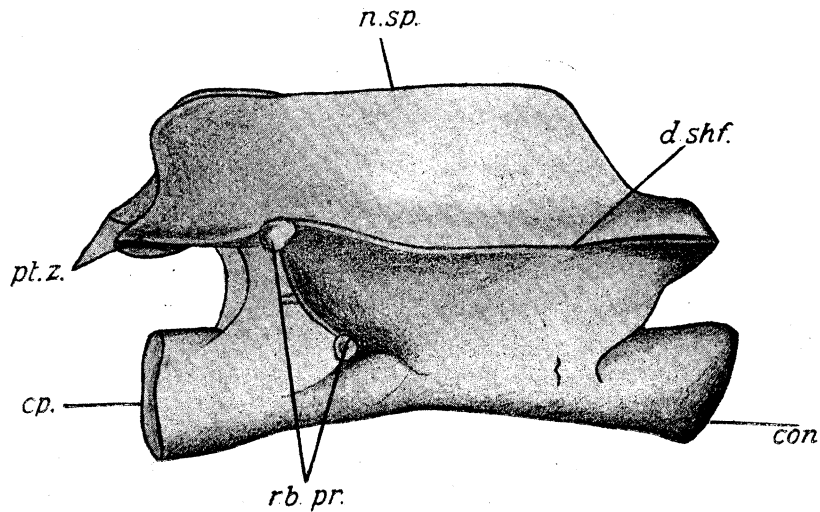
That the so-called odontoid process is the intervertebral element is certain, from the fact that it is a projection of the vertebral body, on the two lateral aspects of which there are the cups for the articulation with the occipital condyles. On the anterior portion of the dorsal surface there is a median ridge-like structure, the neural spine, whose posterior wall forms the supradorsal. There are two lateral shelf-like projections of the neural arch, which are formed by the projections of the connective tissue arches. There is a slight ventral outward projection, which is formed by the parapophysis, which is almost at the middle line of the centrum. The posterior end of the centrum has a cup for articulation with the ball of the next vertebra.

An Adult Typical Trunk Vertebra. (Text-fig. 2.)

The neural arch has the neural spine from the beginning of the vertebra up to the supradorsal element ; the latter structure forms the posterior boundary of it. There are dorsal shelf-like structures, but at the middle of the vertebra, where there were formerly cartilaginous dorsal arcualia, there are lateral projections for the diapophyses which are slightly below the level of the dorsal shelf-like structure. There are also ventral outward and backward projections, formed from the parapophyses. The vertebra has ball at the anterior end and socket at the posterior, *i.e.*, it is opisthocœlous.



TEXT-FIG. 1.—Figure of an adult atlas (first) vertebra. *cp.*, cup for articulating with the condyle of the skull and also cup for articulating with the second vertebra; *od.pr.*, odontoid process; *pt.z.*, post-zygapophysis.

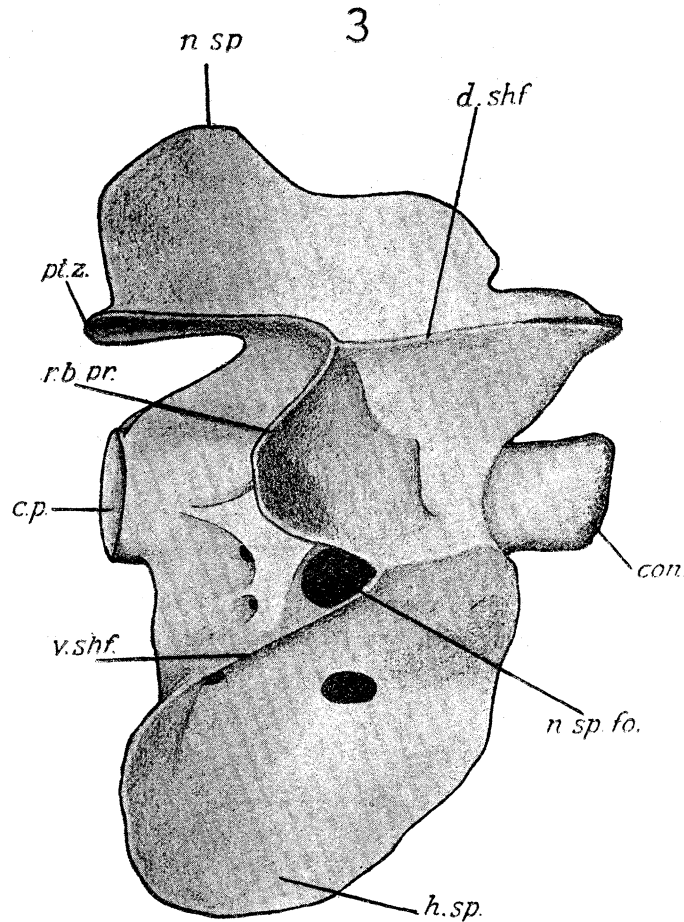


2

TEXT-FIG. 2.—Figure of an adult trunk vertebra. *con.*, condyle (ball) of the vertebra; *cp.*, cup for articulating with the next posterior vertebra; *d.shf.*, dorsal shelf; *n.sp.*, neural spine; *pt.z.*, post-zygapophysis; *rb.pr.*, bifurcated rib bearer.

An Adult Typical Tail Vertebra. (Text-fig. 3.)

The neural arch and the centrum have just the same structure as in the trunk vertebra. At the ventral region there is the hæmal arch with hæmal spine, and the posterior ventral wall is formed by the infraventral body.



TEXT-FIG. 3.—Figure of an adult tail vertebra. *con.*, condyle (ball) of the vertebra; *cp.*, cup for articulating with the next posterior vertebra; *d.shf.*, dorsal shelf; *n.sp.*, neural spine; *n.sp.fo.*, foramen for the spinal nerve; *pt.z.*, post-zygapophysis; *rb.pr.*, bifurcated rib bearer; *v.shf.*, ventral shelf; *h.sp.*, hæmal spine.

Discussion.

It is now a well-established fact that the notochord of Urodela has two sheaths. First, the *elastic sheath* (*primary chordal sheath*, KLAATSCH, 1897), which arises directly from the chorda when there are only a few vacuoles in it. Vacuolation increases to such an extent that chorda cells are only present at the periphery forming the chordal epithelium, and then the second layer of the chorda sheath or the fibrillar layer (*secondary chordal sheath*, KLAATSCH, 1897), or *inner sheath* (GOETTE, 1875), or *elastica interna* (GADOW, 1896), appears between the *elastica externa* and the peripheral chordal epithelium.

According to GADOW (1896) the skeletogenous layer surrounds the notochord uniformly as an undifferentiated structure. There is no trace of segmentation into the vertebral and the intervertebral bodies till the formation of the dorsal arcualia in the vertebral region. He proposed to give the name "*membrana reuniens*" to this undifferentiated layer and to the remnants of it which remain after the cartilaginous structures are formed from it. Its remnants persist as the perichondrial layer of the cartilaginous structures. The dorsal arcualia become cartilaginous at the same time as the skeletogenous structures of the intervertebral region. This intervertebral ring of cartilage, according to GADOW, is formed from four different cartilage centres, viz., a pair of interdorsalia above and a pair of interventralia below. The thickness of the *membrana reuniens* in the vertebral (centrum) region is different from its thickness in the intervertebral region, so that the two structures, namely, the vertebral and the intervertebral bodies are at different levels. This has led some to the mistake of homologizing the intervertebral cartilage in Urodela with the cartilaginous centra of the Dipnoi and Elasmobranchs.

The present writer's observation shows clearly that it is possible to differentiate the skeletogenous layer outside the notochord into perichordal rings and into mesenchymatous tissues filling up the interspaces between them, both together constituting the perichordal tube. GADOW's definition of "*membrana reuniens*" is wrong, because the intervertebral cartilage is formed from this perichordal ring and the mesenchymatous tissue between two successive rings becomes ossified, forming an hour-glass shaped centrum. The waist of the hour-glass corresponds to the intermyotomal (vertebral) region, for there is no other structure there besides this mesenchymatous tissue. The two free ends enclose the perichordal ring (or intervertebral cartilage) which is thus partly surrounded by the osseous hour-glass, so that there is only a narrow space left at the middle portion surrounding each perichordal ring between two consecutive hour-glasses.

The sclerotomic perichordal ring becomes cartilaginous all at once, and so there is no justification for saying that it is derived from four cartilaginous centres. The Russian zoologist EMELIANOFF (1925) has also failed to find the four different cartilaginous centres for the formation of the intervertebral cartilage. Surrounding the middle of each intervertebral cartilage is a space left between the successive osseous vertebral centra. Through each of these spaces a regular strand of connective tissue cells grows into the intervertebral ring of cartilage from all directions. This has not been described by any previous workers. GRAHAM KERR (1921) has stated that the intervertebral cartilage increases considerably in thickness, bulging out between the adjacent somewhat expanded ends of the bony tube. It seems that the connective tissue cells which cut into the intervertebral cartilage have been mistaken for a "bulging out" by GRAHAM KERR, as he could not differentiate the connective tissue cells from the intervertebral cartilage.

The vertebræ of *Triton vulgaris* are opisthocœlous so that the connective tissue cells grow in a slanting direction, caudo-cranially, dividing the intervertebral ring of cartilage

into the ball and the socket, the ball being in front of a vertebra and the socket at the back. The connective tissue cells split up into two parts. Ultimately these connective tissue cells become cartilaginous, but one can easily differentiate the structure of the intervertebral cartilage from the cartilaginous cells of the connective tissue at the edge of either the ball or the socket. Between ball and socket there appears a synovial cavity which facilitates the flexibility of the vertebræ. GRAHAM KERR has surmised that in completely ossified Urodela the joint may be formed by softening of the cartilage along what would be the surface of the joint, or that a layer of cartilage may be liquefied, so that the intervertebral cartilage is completely divided, but of this the present writer could find no evidence.

There is a controversy regarding the formation of the *intravertebral* cartilage which is formed in the vertebral region, replacing the notochord. There are two schools—LWOFF (1893), ZYKOFF (1893) and GADOW (1896) belong to one, which believes that it is formed by the migration of cartilaginous cells from intervertebral cartilage, which rupture the sheath of the notochord. GEGENBAUR (1862), FIELD (1894-5), EBNER (1896), KLAATSCH (1897) and SCHAUINSLAND (1906) belong to the other, who hold that it is formed from the notochordal cells. The observations of the present writer support the latter school.

The cartilaginous elements of the intervertebral as well as intravertebral bodies are evacuated by bone-marrow. Only the cartilaginous cells which are formed from the connective tissue cells, which cut in the intervertebral cartilage to form ball-and-socket, remain in cartilaginous condition throughout life.

According to GADOW (1896) and workers previous to him the dorsal arcualia are formed first as aggregations of sclerotomic cells, corresponding to the posterior (caudal) half of each myotome, just in front of the intermyotomial blood vessel. Corresponding to the anterior (cranial) portion of the myotome there is the spinal nerve ganglion with its nerve. The cartilaginous dorsal arcualia do not sit directly on the elastica externa. But SCHAUINSLAND (1906) contradicted GADOW. The recent worker EMELIANOFF (1925) has not touched this point. The observation of the present writer definitely supports the views of GADOW (1896). Even the figure given by SCHAUINSLAND (1906) on p. 491 contradicts his own statement.

All the workers, including EMELIANOFF (1925), assert that the arch of one side eventually meets its fellow on the other side, enveloping the spinal cord, but the present writer's observation has definitely proved that there is a third piece of cartilage distinct from the cartilaginous structures of the two sides. This third piece should be called "supradorsal."

The anterior portion of the basidorsal cartilages on two sides are not connected dorsally by cartilage, but they are connected by connective tissue. The posterior portion of it has the supradorsal to complete the neural arch. This supradorsal projects caudalwards, where there are no basidorsals.

The formation of zygapophyses has not been touched on by GADOW. Miss PLATT

(1897), who worked on *Necturus*, says that the neural arches become connected with one another at their dorsal extremities by a pair of parallel longitudinal bars of procartilage, which break up into two, to form the articulation of the vertebra. Miss PLATT has not mentioned how it breaks up into two. SCHAUINSLAND (1906) has stated that the dorsal part of the upper arches broadens out to articulate with the next arch.

According to the present writer, on the lateral aspect of the caudal portion of the backwardly projected supradorsal, just posterior to the dorsal portion of the neural arch, there are formed two aggregations of sclerotomic cells. The myotomes of two sides do not unite mid-dorsally, but are in contact with these sclerotomic aggregations on the two sides, which look like the myotomes bent over the spinal cord.

These aggregations of sclerotomic cells continue cranially and caudally into the arches of two different vertebræ, in a slanting manner. These are the " dorso-intervertebral " masses. After they become procartilaginous a strand of connective tissue cells cuts them horizontally in two pieces. These procartilaginous pieces become cartilage, and the connective tissue cells split up into layers, keeping the direction of their ingrowth. The space between the two is the synovial cavity, and the connective tissue cells become procartilaginous. The upper or the dorsal ones articulate with the supradorsal to form the post-zygapophyses. The lower or the ventral ones articulate with the anterior region of the next neural arch to form the pre-zygapophyses, and the gap between the two becomes the synovial cavity.

GEGENBAUR (1862), GADOW (1896), SCHAUINSLAND (1906) and all the principal workers held that the dorsal arcualia were the only structures responsible for the formation of the entire neural arch. Apart from the cartilaginous basidorsal there are formed simultaneously membranous arches which fill up the spaces between the two consecutive cartilaginous basidorsals. Support to this statement has been given by EMELIANOFF (1925), who has recorded that in *Urodela* in the mesenchyme stage there is, apart from the basidorsal, also an aggregation of mesenchyme, which from its position and form reminds one very much of an arch. This aggregation is not retained long and soon disintegrates.

The present writer differs from EMELIANOFF (1925) considerably. The structure of the mesenchymatous tissue is quite different from the structure of the sclerotomic arch of the basidorsal. The present writer has not observed a single section which shows the disintegration of cells of these connective tissue arches. These arches soon turn into bone, leaving merely a space above the intervertebral cartilage, where only the fibrous layer persists in order to give facility of movement to the vertebræ. It follows that two bony arches are formed between each two consecutive basidorsals. The front one joins the cartilaginous basidorsal in front, and the hinder one joins the basidorsal behind; between the two there remains the fibrous layer in which the zygapophyses are embedded. EMELIANOFF (1925) saw the posterior bony arch, but failed to find the anterior or tissue arch.

Another point overlooked by EMELIANOFF is that the connective tissue arch is at

right-angles to the centrum, but the basidorsals (dorsal arcualia) are not. They are curved, so that in a sagittal section in which portions of the dorsal arcualia appear, the connective tissue arches are not seen because they are at a different level. The roof of the neural arch is not formed by the direct junction of the two sides of the arch, but, as we have already seen, by the supradorsal. This piece carries projections on its sides where the basidorsals meet it; these projections form a shelf-like structure, which can be found even in the adult skeleton.

The origin of the dorsal (neural) spine in Urodela has not been dealt with by any previous worker; it has been tacitly assumed that it is formed from a mid-dorsal union of the basidorsals. What actually happens is that it originates from the mid-dorsal roofing of the connective tissue arch. The supradorsal forms only a curved wall at the posterior end of the vertebra.

The most striking fact described in this paper, which has not been recorded by any previous worker, is that part of the dorsal arcualia, *i.e.*, except the supradorsal, degenerates. The degeneration does not take place in the basidorsal as a whole, but cartilaginous cells together with the inner perichondrial layer degenerate, leaving behind the outer perichondrial layer which is converted into bone.

If we go through the series of transverse sections of a degenerated basidorsal we find, first, the outer perichondrium, beyond which there is the connective tissue to complete the arch, and the differences of these two tissues can very easily be detected. The thickness of the upper (or roofing) connective tissue is much greater than that of the outer perichondrial layer of the degenerated basidorsal. A transverse section posterior to this region shows that, instead of the connective tissue roofing the space between two degenerated basidorsals, we get the supradorsal, which retains its cartilage cells, together with the dorsolateral posterior cartilages on two lateral sides to form the posterior zygapophyses.

A comparative study of sections of cartilaginous stage with the adult osseous stage shows that the thickness of the connective tissue arches which become osseous in the adult stage is greater than the thickness of the basidorsal arch, because after the degeneration this is represented only by the outer perichondrial layer. The cartilaginous supradorsal element is ultimately ossified and evacuated by bone-marrow, but the pre- and the post-zygapophyses retain their cartilages throughout life.

The ventral arcualia of the trunk region and of the tail region are quite different. The lower arch in the trunk region develops from the membranous stage into an osseous rod, without passing through the cartilaginous stage. These rod-like structures project laterally, not ventrally. GOEPPERT (1895) first noted that in *Triton alpestris* the original basal part of the hæmal arch element, which lies ventral to the vertebral artery, disappears so far as cartilage is concerned and is replaced by a thin rod of bone. The rib-bearer, which according to him is an outgrowth of the hæmal arch element, is cartilaginous. This cartilaginous rib-bearer fuses completely with the neural arch. GOEPPERT'S explanation has been quoted by GADOW and SCHAUINSLAND.

The hæmal arch element according to GOEPPERT has no direct relation with the rib-bearing process, since the two structures are independent in origin. Support has been given to this view by GAMBLE (1922), who worked on *Necturus*, and the Russian zoologist EMELIANOFF (1925) has also supported this statement.

Concerning the lower (hæmal) arch of the tail region GADOW (1896) says that the ventral arcualia lie as a rule in a slightly more caudal position than the corresponding dorsalia. These ventralia (basiventralia according to GADOW) ultimately meet and fuse with each other below the caudal vessels. The statement of GADOW (1896) has been corroborated by SCHAUINSLAND (1906) and from the figure given in his paper it seems that it is only the cartilaginous arches which ultimately form the osseous hæmal arch.

According to the present writer the hæmal arch in the tail region is formed in the middle region of the vertebra. The basiventral of one side does not meet directly that of the other, but there is a third piece corresponding to the supradorsal of the neural arch elements intervening between them. This third piece may be called "infraventral"; it has not been seen by any previous worker. Just as in the case of the basidorsals successive basiventrals are connected by a belt of connective tissue, which become ossified into anterior and posterior bony arches separated by unossified tissue which forms a flexible joint. From the middle of the floor formed by the union of a pair of these arches there projects the *hæmal-spine*, which has nothing to do with the infraventral cartilage—this only forms a pad on its posterior boundary. As in the case of the basidorsals the cartilaginous cells of the basiventrals degenerate together with the inner perichondrial layer. The cartilage of the infraventral element remains intact. When the degeneration is complete it is the outer perichondrial layer, together with the cartilaginous infraventral element *plus* the connective tissue arches in front and behind, which form the hæmal arch.

The thickness of the connective tissue arches is greater than the thickness of the basiventral arch, after the degeneration, because this latter is represented only by the outer perichondrial layer. At a later stage all these elements become osseous, so that the thickness of the whole hæmal arch differs in different regions. The infraventral cartilage undergoes no degeneration, but ultimately becomes osseous, so that in the adult stage it is a massive structure and is evacuated by bone-marrow cavities. Such cavities have not been previously described in the vertebral column of Urodela.

The question next arises, What is the exact relationship between the posterior portion of the skull and the first (atlas) vertebra? We know that in the secondary segmentation of the skeletogenous tissues the caudal half of one primary segment unites with the cranial half of the segment behind. Each myotome has a spinal nerve ganglion opposite its cranial half and a cartilaginous arch opposite its caudal half. The posterior wall of the auditory capsule corresponds to the caudal half of a myotome. The vagus nerve ganglion next to it corresponds to the cranial half of the next segment. These two half segments form a complete secondary segment. Following this there is the occipital arch

corresponding to the caudal half of a primary segment, but instead of having a nerve ganglion for the next cranial half we get an intercalated arch through which a nerve passes.

If we now examine the column starting from the second vertebra, which is the first vertebra having a rib, we see that this arch corresponds to the caudal half-segment of a myotome; the cranial half of this has a nerve ganglion. In front of this ganglion there is an arch corresponding to the caudal half of the myotome in front; this arch is the first (atlas) arch proper. Instead of having a nerve ganglion for its cranial half, we get an intercalated arch, so that the cranial half of the occipital segment is occupied by this arch. Half of this intercalated arch becomes added to the first (atlas) arch proper, as cups, and the other half goes to the occipital arch, as condyles; so that the first (atlas) vertebra has more than one pair of dorsal arcualia, viz., its own arcualia together with the two articular cups. This intercalated arch is not complete dorsally but deflected lateralwards. Although HOFFMANN (1878) had suggested that the atlas vertebra was a double vertebra, it is now proved for the first time that he is partly correct.

When this intercalated arch is in a procartilagenous stage, connective tissue cells grow in a slanting manner from two sides, as they do in the division of the other intervertebral cartilages. The connective tissue cells slant inwards and caudally, so that the balls (occipital condyles) are in front and the sockets behind. The connective tissue cells grow in such a way as to form an inverted "U"; the two limbs of the "U" form the condyles, and the base of the "U" forms from the intervertebral cartilage between the occipital segment and the atlas segment, so that the two condyles are wide apart.

PARKER (1882) has stated that the odontoid-like process is formed by a pair of cartilages derived from the posterior parachordals; but this odontoid-like process is inside, not outside, the bony cone. GADOW (1896) has suggested that it represents the basiventral element of this region; but that is absurd, since the basiventral element is outside the bony cone. According to GADOW (1896) the atlas of Urodela is not homologous to the atlas of Amniota. This is certain, since the animal in question has 10 cranial nerves instead of 12 or more.

We know that the occipital arch marks the posterior boundary of the cranium. Therefore the condyles, the cups and the odontoid-like process, lying between the atlas (first) arch proper and the occipital arch proper, can collectively be called the proatlas.

We know that in Elasmobranchs the ribs are connected with the centrum by means of a basal stump (basiventral element) which is situated ventral to the vertebral artery. In Urodela on the contrary the ventral head of the rib is attached to a process of the neural arch above the vertebral artery. If the second attachment were brought about by the simple dorsal shifting of the rib and the basal stump, the relation of the vertebral artery with these structures would be necessarily changed. Obviously this attachment is a new one. This explanation was given by RABL (1892). The most generally accepted view on this subject was given by GOEPPERT (1895).

According to GOEPPERT the rib is an outgrowth of the basal stump, while RABL

holds that it is of independent origin. In Triton the basal portion of the basal stump is replaced by an osseous rod ; the distal end of the basal stump has the attachment of the rib.

GAMBLE (1922), who worked on *Necturus*, says that the rib is not an outgrowth of the basal stump, but is independent in origin. The distal end of the rib also develops independently within the myosepta. EMELIANOFF (1925) has stated that the first rudiments of an Urodelan rib appears as concentrations of cells in the myosepta. Ribs become cartilaginous first at their distal ends. The rib grows proximally and unites itself secondarily with the rib-carrier. The ribs of the Urodela are according to their position on the horizontal myoseptum homologous with the upper ribs of fish.

The present writer's observations lead him to conclusions similar to those of EMELIANOFF. In the trunk vertebræ the distal end of the rib in the myoseptum develops first ; then the osseous basal stump ; then it is followed by an independent rib-bearing process on the side of the basidorsal. These two, namely, the basal stump and the rib-bearer, meet and are also joined by the proximal part of the rib, but although the ventral head of the rib is attached to a process above the vertebral artery there is a third attachment to the centrum ventral to this artery.* The two conspicuous heads of the rib obviously correspond to a bifurcated "Tubercle" of the ribs of Amniota, but the third attachment is obviously the true homologue of the head of the rib of Amniota.

In the tail vertebra, the parapophyses originate from the hæmal arch as a dorsal outgrowth. At a later stage their free ends join with the rib-bearing processes (diapophyses) and between the diapophyses and the parapophyses there is the vertebral artery. So that in the tail region the arrangement can be compared with that in Amniota, in which the head of the rib lies beneath the vertebral artery and the tubercle above it.

Summary.

1. The sclerotomic cells, just after liberation from the ventromedian corner of each somite, aggregate round the notochord corresponding to the middle portion of the myotome forming the perichordal rings.

2. The notochord, which primarily has a uniform diameter throughout, undergoes moniliform differentiation. Dilatations are confined to the middle portion of the myotome, while the constrictions occur in the intermyotomial regions.

3. Ordinary mesenchymatous cells fill up the interspaces between the successive perichordal rings, forming a continuous tube-like structure outside the sheath of the notochord, called the perichordal tube.

4. The perichordal tube follows the moniliform shape of the notochord.

5. The perichordal tube becomes ossified, forming thus a series of bony rings, but the perichordal rings become cartilaginous. Each perichordal ring is overlapped by these bony rings ; but the overlap of one does not meet the overlap of the next, so that the middle of the perichordal ring remains unprotected.

* See note on p. 422 referring to P. GRAY'S paper.

6. Each bony tube forms an hour-glass shaped centrum. The narrow waist of the hour-glass is the vertebral region, and the two wide ends where the cartilaginous cells forming the perichordal rings are situated are the intervertebral regions.

7. The intervertebral ring of cartilage has only one centre of chondrification, contrary to the views of GADOW.

8. Connective tissue cells grow into the cartilaginous perichordal ring in a caudal to cranial direction, forming a complete arc through the interspace between the two successive hour-glass shaped centra, and then a split appears in the middle region of the line of this arc of connective tissue cells, thus forming a synovial cavity. Thus the intervertebral cartilage is divided into a ball and a socket; the ball articulates with the front end of a vertebra and the socket with the back of the previous vertebra. The connective tissue cells lining the synovial cavity become cartilaginous, forming the surfaces of the ball and socket.

9. The notochordal cells in the middle of each centrum become converted into cartilage. This cartilage is the *intravertebral cartilage*. It eventually becomes ossified and then hollowed out by marrow cavities.

10. Between the occipital arch and the atlas (first) arch proper is a pair of intercalated cartilaginous arches, which extends horizontally outwards, not laterally. Connective tissue cells grow into these intercalated arches, dividing them into two, just as in the case of the intervertebral cartilages. These arches are outside the notochord and, unlike the intervertebral cartilage, do not crush the notochord nor do they unite with one another. Thus the connective tissue cells cut the bases of the arches into two balls and two sockets forming two arcs.

11. Between the two balls, where originally there was the notochord, there is formed a projecting cartilaginous piece from the intervertebral cartilage between the occipital arch and the atlas arch proper; this is the so-called odontoid process. The atlas has thus more than one pair of dorsal arcualia. It has a portion of the intercalated cartilaginous arch, forming cups, *plus* the dorsal arcualia proper, and the portion of the intercalated arch forming the cups and the odontoid-like process may be called the proatlas.

12. Instead of having the cartilaginous dorsal arcualia formed by the fusion of the basidorsal of the right with the basidorsal of the left there is a third distinct piece of cartilage—the supradorsal—intervening between the basidorsals to complete the arch.

13. The anterior portions of the dorsal arcualia are not connected in the mid-dorsal line by cartilaginous structures but have a connective tissue roofing with lateral out-growths projecting dorsally.

14. There are two connective tissue arches and not one for each vertebra, as EMELIANOFF states. One connective tissue arch is formed in front of the cartilaginous dorsal arcualia of each vertebra and is almost at right-angles to the centrum. It has two pillar-like structures with a separate roofing, with two projections laterodorsally.

15. The other connective tissue arch is formed at the back of each pair of cartilaginous dorsal arcualia and has the same structure as that in front of it, and the supradorsal forms the roof for the cartilaginous dorsal arcualia, which are deflected backwards.

16. From the middle portion of each roof of the connective tissue arch there arises a projection—the neural spine.

17. Between the two consecutive cartilaginous dorsal arcualia therefore, there are two bony arches formed from connective tissue, one (the posterior) attached to the basidorsals in front, and the other (the anterior) attached to the basidorsals behind. Between the posterior connective tissue arch of one vertebra of the anterior connective tissue arches of the next there is a flexible region of connective tissue allowing of movement.

18. At the sides of the caudal portion of the supradorsal cartilage there are formed two aggregations of sclerotomic cells connecting the two consecutive neural arches in a slanting manner. The myotomes of two sides do not unite mid-dorsally, but they are in contact with these sclerotomic aggregations. This sclerotomic aggregation should be called *dorsointervertebral*.

19. The dorsointervertebral body becomes procartilaginous and then a strand of connective tissue cells grow into it. A split occurs within this connective tissue strand dividing the dorsointervertebral body into two. The portion attached to the lateral sides of the supradorsal forms the *post-zygapophysis*, which is at a higher level than the other portion which is attached to the anterior portion of the next neural arch which forms the pre-zygapophysis. Between the two there is the synovial cavity.

20. Both the pre-zygapophysis and the post-zygapophysis become cartilaginous, with a lining of a different kind of cartilaginous cells on the surface of the synovial cavity, formed from the connective tissue cells which migrated inwards. These cells remain cartilaginous throughout life.

21. The connective tissue arches become osseous and the lateral projections of their roofs, together with the connective tissue roof uniting the cartilaginous arcualia with their similar projections, form the dorso-lateral shelf-like structure found in the dried adult vertebra.

22. The cartilaginous cells of the basidorsals together with their inner perichordial layers degenerate.

23. The cartilaginous ventral arcualia of the tail vertebra are not formed by the fusion of the basiventral of the right with the basiventral of the left; there is a third distinct piece of cartilage between them, which we shall term the *infraventral*.

24. A connective tissue arch is formed both in front of and behind the cartilaginous ventral arcualia of the tail vertebra. Each arch is almost at right-angles to the centrum. It has two pillar-like structures with a separate roof connecting the two pillars, with projections on the two sides.

25. In the middle portion of each third piece of connective tissue arch, which connects the two lateral pillars, there forms a projection—the hæmal spine.

26. There is no degeneration of the cartilaginous supradorsal, but when it eventually becomes ossified it is hollowed out by marrow cavities.

27. The outer perichondrial layer of the basidorsals becomes osseous.

28. The cartilaginous cells of the basiventrals on the two ventro-lateral sides of the notochord, together with their inner perichondrial layer, degenerate, but the outer perichondrial layer, just as in the basidorsals, becomes ossified and hollowed out by marrow cavities.

29. There is no degeneration of the cartilaginous infraventral elements.

30. The occipital condyles and the corresponding cups on the atlas vertebra are hollowed out by marrow cavities, but connective tissue cells which form the surfaces of the balls and sockets become cartilaginous and remain so throughout life.

31. The cartilaginous rib-bearer which forms on the dorsolateral aspects of the basidorsal is hollowed out by bone marrow.

32. The rib forms as an independent aggregation of cells in the septum between two myotomes. This becomes cartilaginous, and becomes secondarily joined (*a*) to an out-growth from the side of the basidorsal which is the diapophysis, (*b*) to an out-growth from the side of the centrum which is the diaapophysis. Both these lie above the vertebral artery and together correspond to the diapophysis of the Amniote vertebra, but there is a third connection with the centrum ventral to the vertebral artery and this corresponds to the true head of the rib in Amniota and its connection with the centrum. In the tail, also the hæmal arch which replaces the rib, is a direct out-growth of the basiventral.

Literature.

ADOLPHI, H. (1897). "Ueber das Wandern der Extremitätenplexus und des Sacrum bei *Triton taeniatus*." 'Morphol. Jahrb.,' vol. 25.

ALBRECHT, P. (1878). "Ueber einen Processus odontoideus des Atlas bei den urodelen Amphibien." 'Centralbl. d. Med. Wiss.'

Idem (1880). "Über den Proatlas, einen zwischen dem Occipitale und dem Atlas der Amnioten Wirbeltiere gelegenen Wirbel und den Nervus Spinalis I.s. proatlanticus." 'Zoo. Anz.,' vol. 3.

Idem (1883). "Note sur le basioccipital des Batraciens anoures," 'Bull. Musée Roy. d'Hist. Nat. de Belgique,' vol. 2.

BARFURTH, D. (1891). "Zur Entwicklung und Regeneration der Chorda dorsalis bei den urodelen Amphibien." 'Anat. Anz.,' vol. 6.

DUGES, A. (1835). "Recherches sur l'ostéologie et la myologie des Batraciens à leurs différens âges." 'Mem. Institut France' ('Sci. Math. et Phys.),' vol. 6, 18 plates.

EBNER, V. (1896). "Über die Wirbel der Knochenfische und die Chorda dorsalis der Fische und Amphibien." 'Sitzber. k. Akad. Wiss. Wien,' vol. 105.

- EMELIANOFF, S. V. (1925). "Zur Frage über die Entwicklung der Wirbelsäule bei den Amphibien." 'Rev. Zool. Russe, Moscow,' 5.1.2, pp. 53-69 (*in Russian*), fig. 5, pp. 70-72 (*Summary in German*).
- Idem* (1925). "Die Entwicklung der Rippen und ihr Verhältnis zur Wirbelsäule." 'Rev. Zool. Russe, Moscow,' 5.4, pp. 26-48 (*in Russian*), 9 figs. pp. 48, 49 (*Summary in German*).
- FIELD, H. H. (1895). "Bemerkungen über die Entwicklung der Wirbelsäule bei den Amphibien." 'Morphol. Jahrb.,' vol. 22, pp. 340-356, Leipzig, 2 plates.
- FRORIEP, A. (1883). "Zür Entwicklungsgeschichte der Wirbelsäule, insbesondere des Atlas und Epistropheus und der Occipitalregion. I.—Beobachtung an Hühnerembryonen." 'Archiv f. Anat. u. Phys., Anat. Abt.'
- GADOW, H. (1896). "On the Evolution of the Vertebral Column of Amphibia and Amniota." 'Phil. Trans.,' Series B, vol. 187, pp. 1-57, London. (Many figures in the next.)
- Idem* (1901). "Amphibia and Reptilia." (The Cambridge Natural History.)
- GAMBLE, D. L. (1922). "The morphology of the ribs and transverse processes in *Necturus maculatus*." 'Journ. of Morph.,' vol. 36.
- GEGENBAUR, C. (1861). "Ueber Bau und Entwicklung der Wirbelsäule bei Amphibien überhaupt und beim Frosche insbesondere." 'Abh. Naturf. Ges.,' vol. 6, Halle, pp. 179-194. (One plate.)
- Idem* (1862). "Untersuchungen zur vergl. Anatomie der Wirbelsäule bei Amphibien und Reptilien," 4°, Leipzig. (Four plates.)
- GOEPPERT, E. (1895). "Zur Kenntniss der Amphibienrippen: Vorläufige Mittheilung." 'Morph. Jahrb.,' vol. 22.
- GOETTE, A. (1875). "Beiträge zur Entwicklungsgeschichte der Wirbelthiere." 'Archiv Mikrosk. Anat.'
- HASSE, C. (1892). "Die Entwicklung der Wirbelsäule von *Triton taeniatus*." 'Zeitschr. f. Wiss. Zool.,' vol. 53, Suppl.
- Idem* (1892). "Die Entwicklung der Wirbelsäule der ungeschwänzten Amphibien." 'Zeitschr. f. Wiss. Zool.,' vol. 55, pp. 252-265, Leipzig. (One plate.)
- HOFFMANN, C. K. (1878). "Beiträge zur vergleichenden Anatomie der Wirbelthiere. IX.—Zur Morphologie der Rippen." 'Niederl. Arch. Zool.,' vol. 4, plate 12-13.
- HOWES, G. B. (1893). "Notes on the Variation and Development of the Vertebral and Limb-skeleton of the Amphibia." 'Pro. Zool. Soc. London,' pp. 268-278. (Numerous figures in the text.)
- KAPELKIN, W. (1900). "Zur Frage über die Entwicklung des axialen Skeletes der Amphibien." 'Bull. Soc. Imp. d. Naturalistes de Moscou,' vol. 14.
- KERR, J. GRAHAM (1921). "Text-book of Embryology," vol. 2.
- KLAATSCH, H. (1897). "Über die Chorda und die Chordascheiden der Amphibien." 'Verhandl. d. Anat. Gesell.,' 11, vers.

- LWOFF, B. (1887). "Vergleichend-anatomische Studien über die Chorda und die Chordascheide," 'Bull. Soc. Imp. d. Naturalistes de Moscou,' No. 2.
- MURRAY, J. A. (1897). "The vertebral column of certain primitive Urodela; Spelerpes, Plethodon, Desmognathus." 'Anat. Anz.,' vol. 13.
- OWEN, R. (1866). "Anat. of Vertebrates," vol. 1, London.
- PARKER, G. H. (1896). "Variations in the Vertebral Column of Necturus." 'Anat. Anz.,' vol. 11, pp. 711-17, Jena.
- PARKER, W. K. (1882). "On the morphology of the skull in the Amphibia Urodela." 'Trans. Linnean Soc. London,' Ser. 2, Zoology, vol. 2, Part 3 (1878-88), 1882.
- Idem* (1882). "On the structure and development of the skull in the Urodeles." 'Trans. Zool. Soc. London,' vol. 11, Part 6.
- PETER, K. (1895). "Ueber die Bedeutung des Atlas der Amphibien." 'Anat. Anz.,' vol. 10, pp. 565-74, Jena.
- PIIPER, J. (1928). "On the evolution of the vertebral column in Birds, illustrated by its development in *Larus* and *Struthio*." 'Phil. Trans.,' Series B, vol. 216, pp. 385-351, Plate 18.
- PLATT, JULIA B. (1897). "The development of the cartilaginous skull and of the branchial and hypoglossal musculature in *Necturus*." 'Morph. Jahrb.,' vol. 25.
- RABL, C. (1892). "Theorie des Mesoderms." 'Morph. Jahrb.,' vol. 19.
- Idem* (1897). "Theorie des Mesoderms." 'I. Teil. Vorwort.,' Leipzig.
- SCHAUINSLAND, H. (1906). "Die Entwicklung der Wirbelsäule nebst Rippen und Brustbein." 'Handbuch der vergl. u. experim. Entw.-lehre der Wirbeltiere, von OSKAR HERFWIG,' vol. 3, Part 2.
- STANNIUS, H. (und SIEBOLD, C. T. von) (1846). "Lehrbuch der vergl. Anatomie,' vol. 2, Wirbeltiere, Berlin.
- STANNIUS, H. (1856). "Handbuch der Zoologie," Teil 2, Buch 2, 'Zool. der Amphibien,' Berlin.
- ZYKOFF (1893). "Über das Verhältniss des Knorpels zur Chorda bei *Siredon pisciformis*." 'Bull. Soc. Imp. Nat. Moscou,' vol. 7.

EXPLANATION OF PLATES.

All the figures, except the text-figures of the adult vertebræ, are microphotographs from actual sections so that the magnification in each case has not been stated.

PLATE 44.

- FIG. 1.—Transverse section through the stage A. *m.*, mesoderm; *nch.*, notochord; *n.p.*, neural plate; *y.*, yolky endoderm cells.
- FIG. 2.—Frontal section through the stage B. *nch.*, notochord; *n.c.*, neural cord; *sm.*, somite.
- FIG. 3.—Frontal section through the 8 mm. stage. *Bd.*, basidorsal; *can.*, central canal of the nerve cord; *mt.*, myotome; *n.c.*, neural cord; *n.g.*, nerve ganglion.
- FIG. 4.—Frontal section through 12 mm. stage. *at.ar.*, atlas arch; *au.cap.*, auditory capsule; *br.*, brain; *cp.*, cup; *conn.*, connective tissue; *nch.*, notochord; *oc.ar.*, occipital arch; *oc.con.*, occipital condyle; *pch.r.*, perichordal ring.

- FIG. 5.—Transverse section through the atlas vertebra at 15 mm. stage. *bd.*, basidorsal; *cp.*, cup of the atlas vertebra; *nch.*, notochord; *n.c.*, neural cord.
- FIG. 6.—Transverse section through the interspace between two consecutive cartilaginous dorsal arcualia at 15 mm. stage. *ao.*, aorta; *conn.ar.*, connective tissue arch; *iv.c.*, intervertebral cartilage; *nch.*, notochord; *n.c.*, neural canal; *sd.*, supradorsal; *s.n.g.*, spinal nerve ganglion.
- FIG. 7.—Sagittal section through the occipital and the atlas regions at 20 mm. stage. *at.ar.*, atlas arch; *cp.*, cup; *conn.*, connective tissue which forms the synovial cavity; *n.c.*, neural cord; *n.sp.I.*, nerve spinalis I (sub-occipital); *n.sp.II.*, nerve spinalis II (hypoglossal); *IID.arc.*, second dorsal arch; *oc.ar.*, occipital arch; *oc.con.*, occipital condyle; *r.b.pr.*, rib bearing process.

PLATE 45.

- FIG. 8.—Transverse section through the trunk vertebra at 20 mm. stage. *ao.*, aorta; *bd.*, basidorsal; *n.c.*, neural cord; *nch.*, notochord; *r.b.pr.*, rib bearing process; *sd.*, supradorsal; *v.a.*, vertebral artery.
- FIG. 9.—Sagittal section through a few neural arches at 20 mm. stage. *bd.*, basidorsal; *pr.z.*, prezygapophysis; *pt.z.*, post-zygapophysis; *sd.*, supradorsal; *sy.c.*, synovial cavity; *s.n.g.*, spinal nerve ganglion.
- FIG. 10.—Transverse section through the tail region at 20 mm. stage. *bl.v.*, blood vessel; *h.ar.*, hæmal arch; *n.c.*, neural cord; *nch.*, notochord; *sd.*, supradorsal; *s.n.g.*, spinal nerve ganglion; *z.*, zygapophysis.
- FIG. 11.—Sagittal section through the atlas region at 25 mm. stage. *at.ar.*, atlas arch; *cp.*, cup; *conn.*, connective tissue which forms the synovial cavity; *oc.con.*, occipital condyle; *s.n.g.*, spinal nerve ganglion.
- FIG. 12.—Frontal section through the occipital and the atlas regions at 25 mm. stage. *cen.*, centrum; *conn.*, connective tissue which forms the synovial cavity; *cp.*, cup; *iv.c.*, intervertebral cartilage; *nch.*, notochord; *oc.ar.*, occipital arch; *oc.con.*, occipital condyle; *od.pr.*, odontoid process.
- FIG. 13.—Frontal section through the same specimen as that of fig. 12, more dorsally. *at.ar.*, atlas arch; *au.cap.*, auditory capsule; *cp.*, cup; *nch.*, notochord; *n.c.*, neural cord; *n.sp.I.*, nerve spinalis I; *oc.ar.*, occipital arch; *oc.con.*, occipital condyle; *r.*, rib; *v.n.g.*, vagus nerve ganglion.

PLATE 46.

- FIG. 14.—Transverse section through the trunk vertebra at 25 mm. stage. *ao.*, aorta; *bd.*, basidorsal; *conn.*, connective tissue forming roof of neural canal; *n.c.*, neural cord; *nch.*, notochord; *r.b.pr.*, rib bearing process.
- FIG. 15.—Frontal section through the centra of a few vertebræ at 25 mm. stage. *conn.*, connective tissue which will form a synovial cavity; *bd.*, degenerating basidorsal; *iv.c.*, intervertebral cartilage; *nch.*, notochord; *r.*, rib; *r.b.pr.*, rib bearing process.
- FIG. 16.—Transverse section through the beginning of a trunk vertebra at 35 mm. stage. *ao.*, aorta; *cen.*, centrum; *conn.ar.*, connective tissue arch; *conn.ar.rf.*, connective tissue arch roof; *iv.c.*, intravertebral cartilage; *nch.*, notochord; *n.c.*, neural cord; *nch.sh.*, notochordal sheath; *pr.z.*, pre-zygapophysis; *pt.z.*, post-zygapophysis; *v.a.*, vertebral artery.
- FIG. 17.—Transverse section of the same stage a little posterior to the above. *bv.*, basiventral; *cen.*, centrum; *conn.ar.*, connective tissue arch; *conn.ar.rf.*, connective tissue arch roof; *iv.c.*, intervertebral cartilage; *n.c.*, neural cord; *nch.*, notochord; *n.sp.*, neural spine; *pap.*, parapophysis; *r.b.pr.*, rib bearing process.
- FIG. 18.—Transverse section of the same, further posterior to the above. *bd.*, basidorsal; *conn.ar.rf.*, connective tissue arch roof; *d.shf.*, dorsal shelf; *in.per.*, inner perichondrium in course of dissolution; *out.per.*, outer perichondrium of basidorsal which ossifies; *r.b.pr.*, rib bearing process.

FIG. 19.—Transverse section through the same vertebra at the extreme posterior end. *ao.*, aorta; *conn.ar.rf.*, roof of connective tissue arch; *cp.*, cup of the vertebra behind; *f.t.*, fibrous tissue; *nch.*, notochord; *nch.sh.*, notochordal sheath; *pr.z.*, pre-zygapophysis; *pt.z.*, post-zygapophysis; *sd.*, supradorsal; *sy.c.*, synovial cavity; *v.a.*, vertebral artery; *v.con.*, condyle of the vertebra behind.

PLATE 47.

FIG. 20.—Frontal section through the dorsal portion of the neural arches at 35 mm. stage. *bd.*, basidorsal; *conn.ar.*, connective tissue arch; *f.t.*, fibrous tissue; *n.c.*, neural cord; *pr.z.*, pre-zygapophysis; *pt.z.*, post-zygapophysis.

FIG. 21.—Frontal section through the centrum at 35 mm. stage. *bd.*, basidorsal; *conn.*, connective tissue forming the synovial cavity; *conn.ar.*, connective tissue arch; *iv.c.*, intravertebral cartilage; *iv.c.*, intervertebral cartilage; *nch.*, notochord; *r.*, rib; *s.n.g.*, spinal nerve ganglion.

FIG. 22.—Sagittal section through the middle of a few trunk vertebræ at 35 mm. stage. *conn.ar.rf.*, connective tissue arch roof; *iv.c.*, intervertebral cartilage; *n.c.*, neural cord; *nch.*, notochord; *sd.*, supradorsal.

FIG. 23.—Transverse section through the middle of an anterior tail vertebra at 35 mm. stage. *cd.ar.*, caudal artery; *conn.ar.rf.*, connective tissue arch roof; *n.c.*, neural cord; *n.sp.*, neural spine; *nch.*, notochord; *r.b.pr.*, rib bearing process.

FIG. 24.—Transverse section through the posterior region of a tail vertebra at 35 mm. stage. *conn.ar.*, connective tissue arch; *ifv.*, infraventral; *iv.c.*, interventral cartilage; *nch.*, notochord; *n.c.*, neural cord; *nch.sh.*, notochordal sheath; *pr.z.*, pre-zygapophysis; *pt.z.*, post-zygapophysis; *sd.*, supradorsal; *sy.c.*, synovial cavity.

FIG. 25.—Transverse section through the tail in the region of the connective tissue arch at 40 mm. stage. *cd.ar.*, caudal artery; *conn.ar.*, connective tissue arch; *conn.ar.rf.*, connective tissue arch roof; *d.shf.*, dorsal shelf; *ifv.*, infraventral; *nch.*, notochord; *n.c.*, neural cord.

PLATE 48.

FIG. 26.—Sagittal section through the middle of a few tail vertebræ at 40 mm. stage. *conn.ar.rf.*, connective tissue arch roof; *f.t.*, fibrous tissue; *ifv.*, infraventral; *nch.*, notochord; *n.c.*, neural cord.

FIG. 27.—Transverse section through a tail vertebra at 40 mm. stage. *conn.ar.*, connective tissue arch; *ifv.*, infraventral; *nch.*, notochord; *pap.*, parapophysis; *r.b.pr.*, rib bearing process; *sd.*, supradorsal.

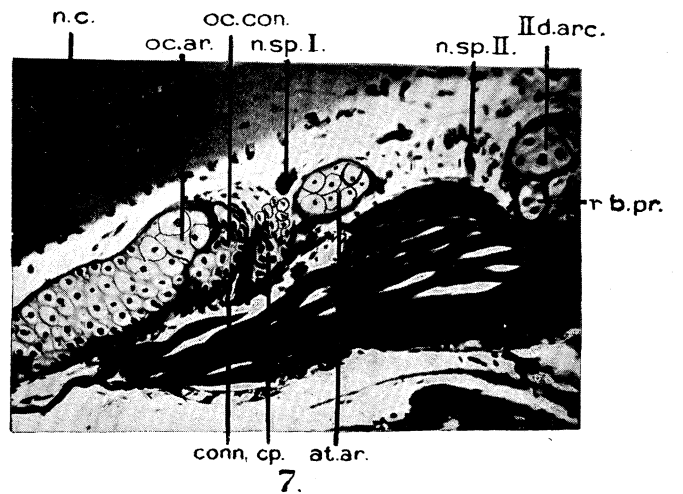
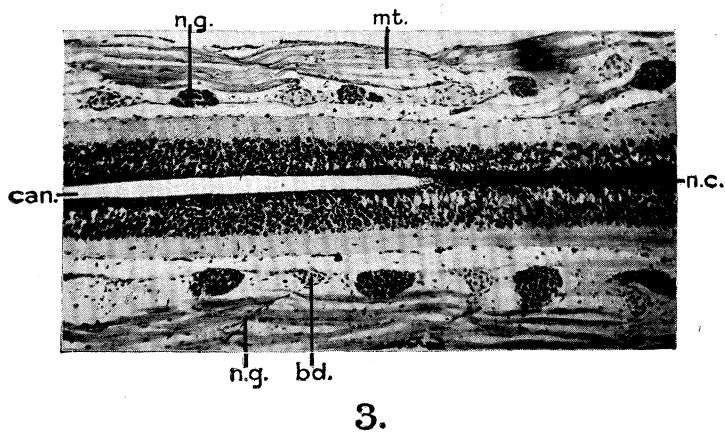
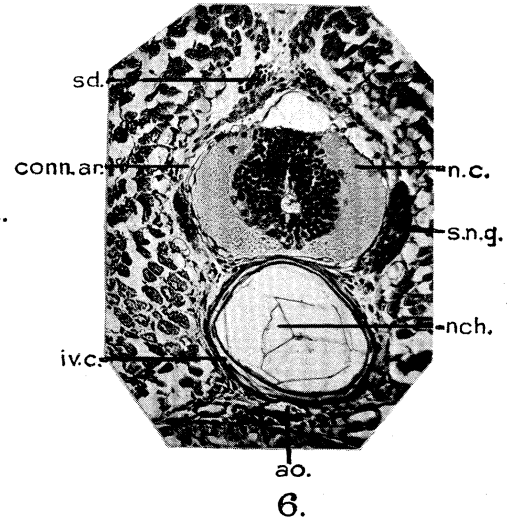
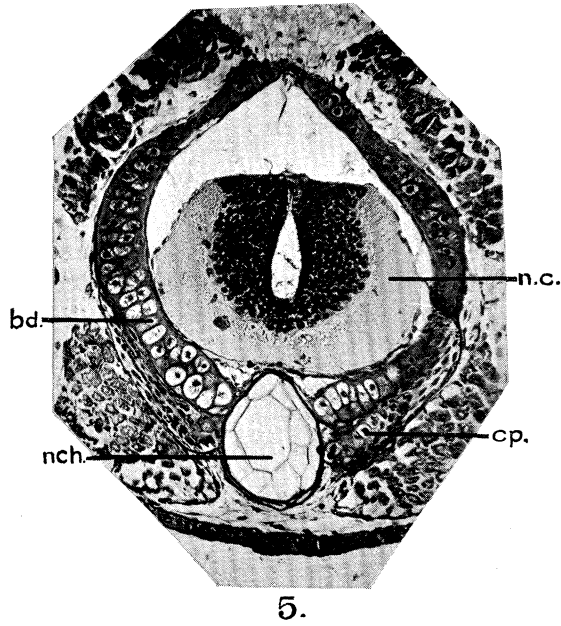
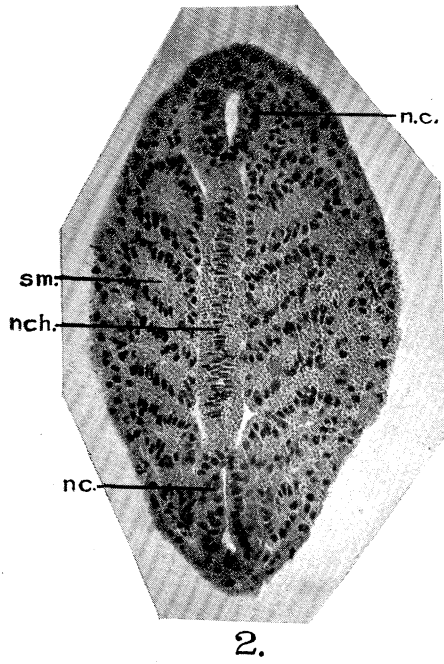
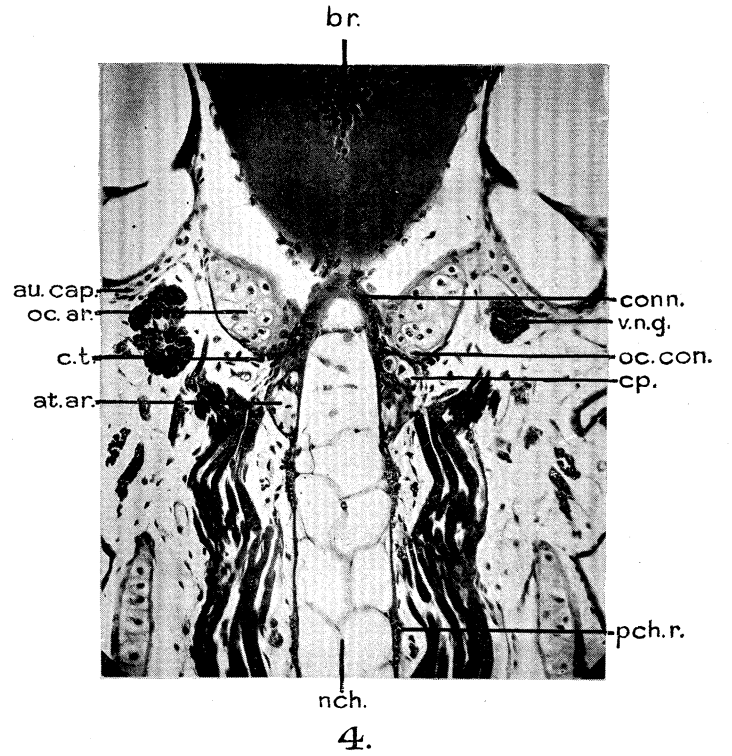
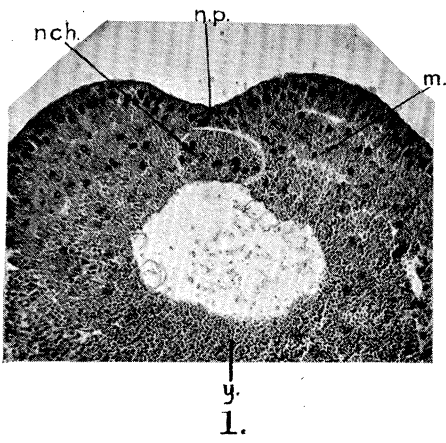
FIG. 28.—Transverse section through the beginning of a trunk vertebra at 65 mm. stage. *conn.ar.rf.*, connective tissue arch roof; *f.t.*, fibrous tissue; *n.sp.*, neural spine; *pr.z.*, pre-zygapophysis; *pt.z.*, post-zygapophysis; *sy.c.*, synovial cavity; *v.a.*, vertebral artery; *v.con.*, vertebral condyle; *v.cp.*, vertebral cup.

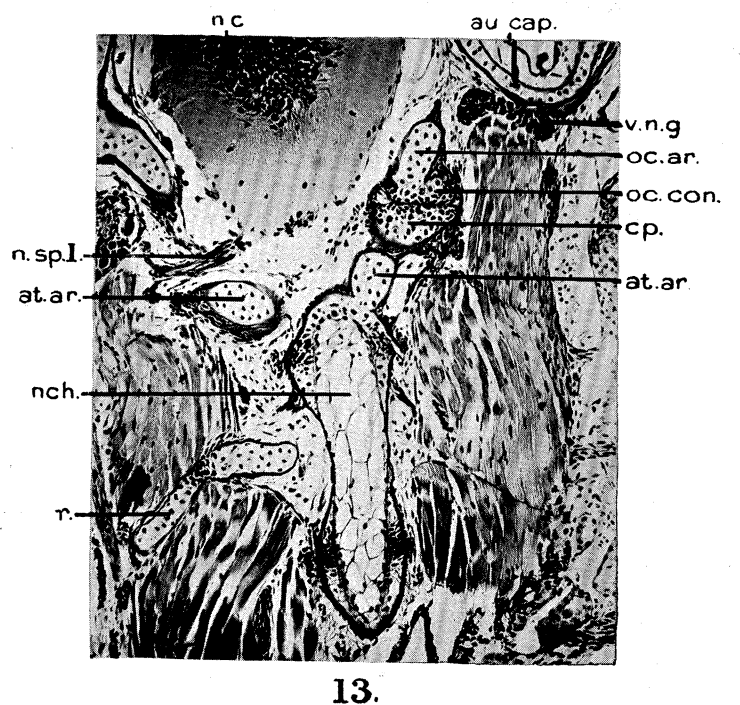
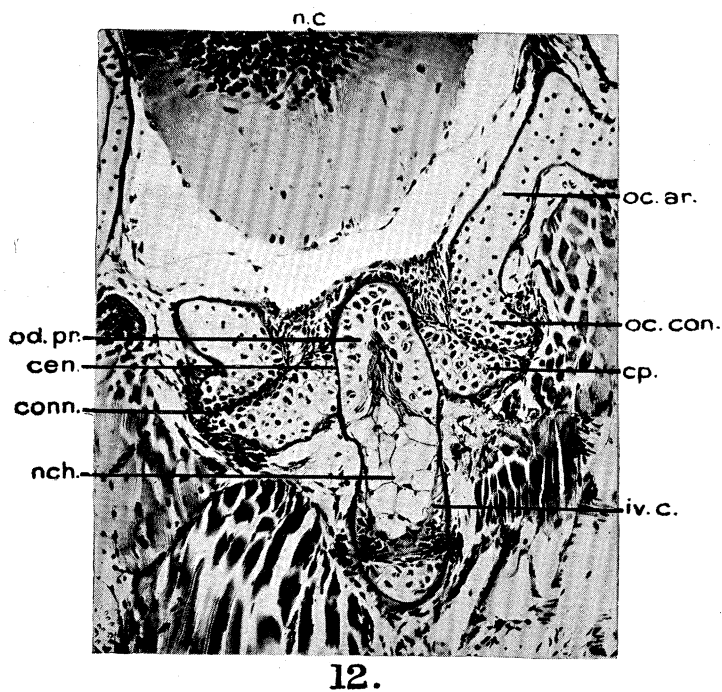
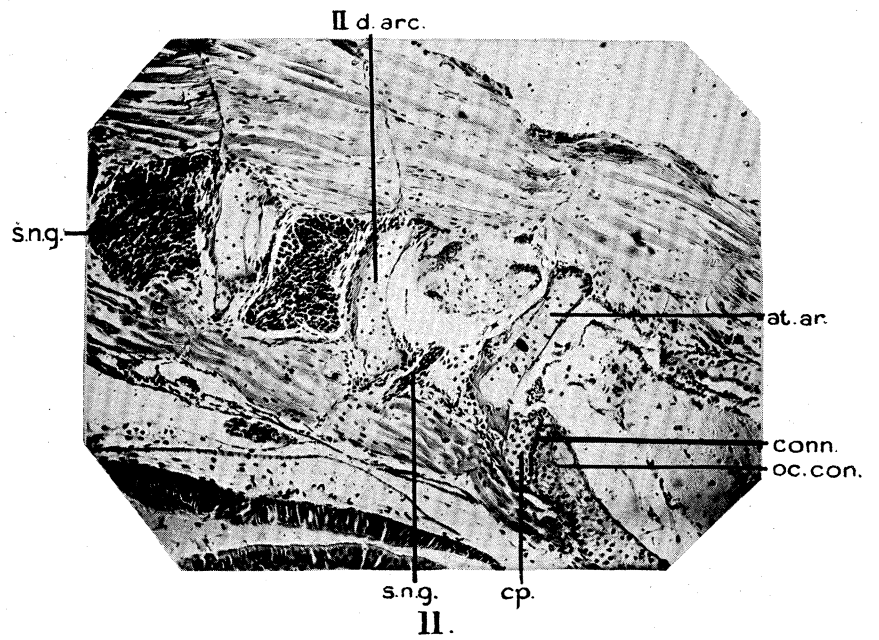
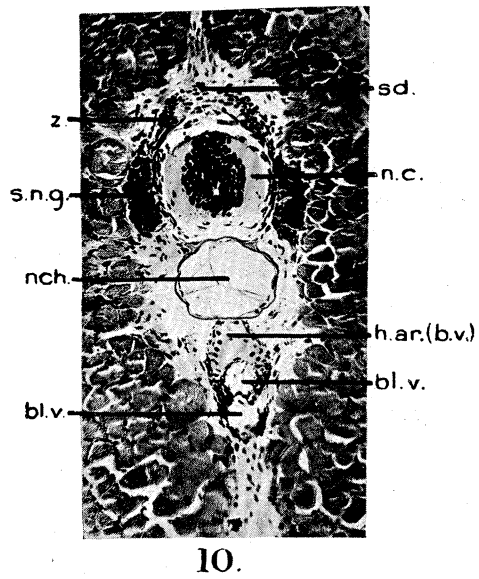
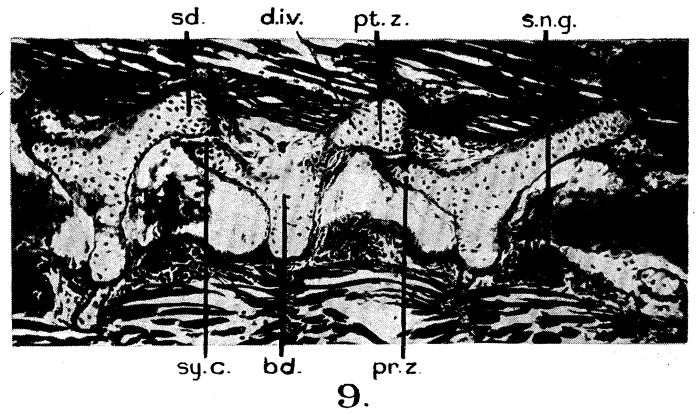
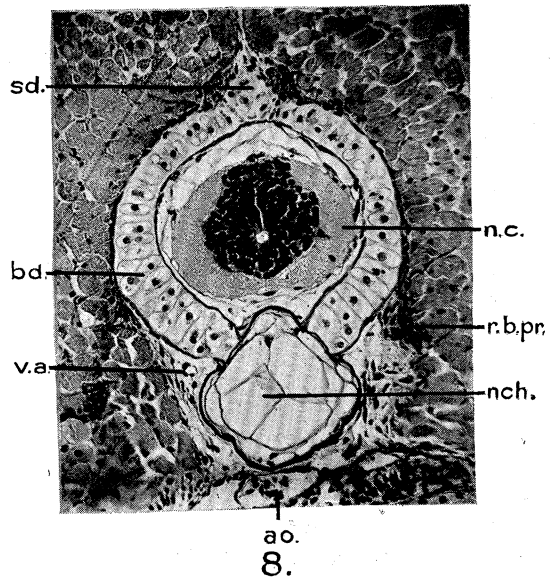
FIG. 29.—Transverse section through the same vertebra a little posterior to the previous figure. *cen.*, centrum; *conn.ar.*, connective tissue arch; *d.shf.*, dorsal shelf; *ma.*, marrow; *n.sp.*, neural spine.

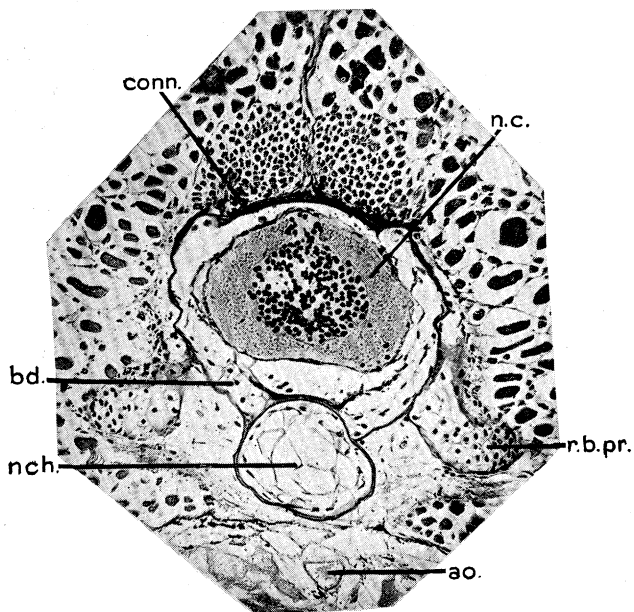
FIG. 30.—Transverse section through the same vertebra further back. *bd.*, basidorsal; *cen.*, centrum; *n.c.*, neural cord; *n.sp.*, neural spine; *pap.*, parapophysis (*i.e.*, the true capitulum); *r.b.pr.*, rib bearing process; *v.a.*, vertebral artery.

FIG. 31.—Transverse section through the end of the same vertebra. *cap.r.*, capitulum of the rib; *conn.ar.*, connective tissue arch; *iv.c.*, intervertebral cartilage; *sd.*, supradorsal; *sy.c.*, synovial cavity; *tu.r.*, tuberculum of the rib.

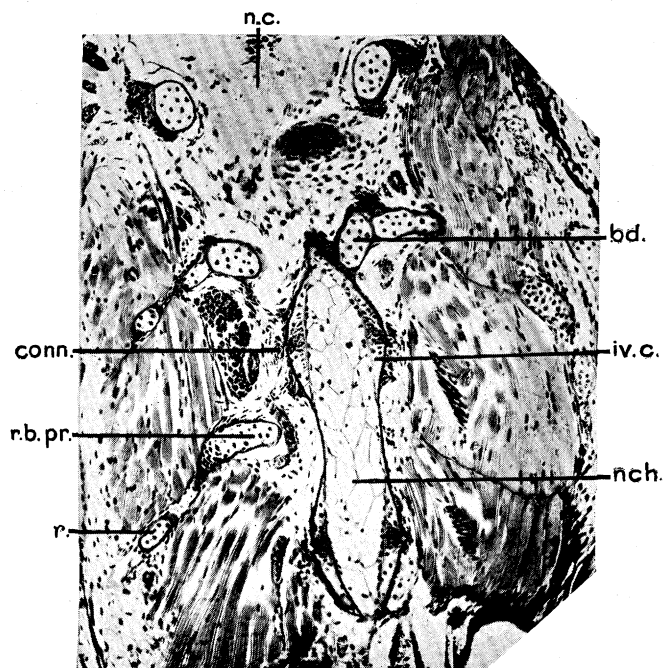
FIG. 32.—Transverse section through the same vertebra at the extreme end of it. *conn.ar.*, connective tissue arch; *conn.ar.rf.*, connective tissue arch roof; *pr.z.*, pre-zygapophysis; *pt.z.*, post-zygapophysis; *sd.*, supradorsal; *v.a.*, vertebral artery; *v.con.*, vertebral condyle.



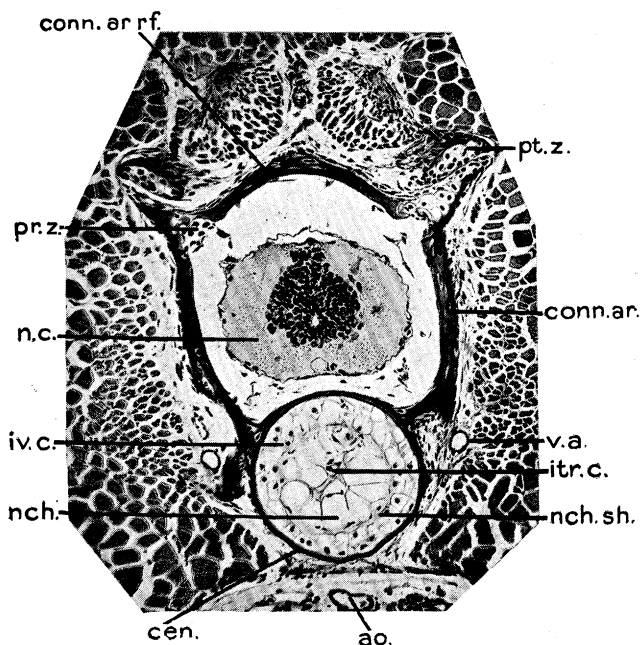




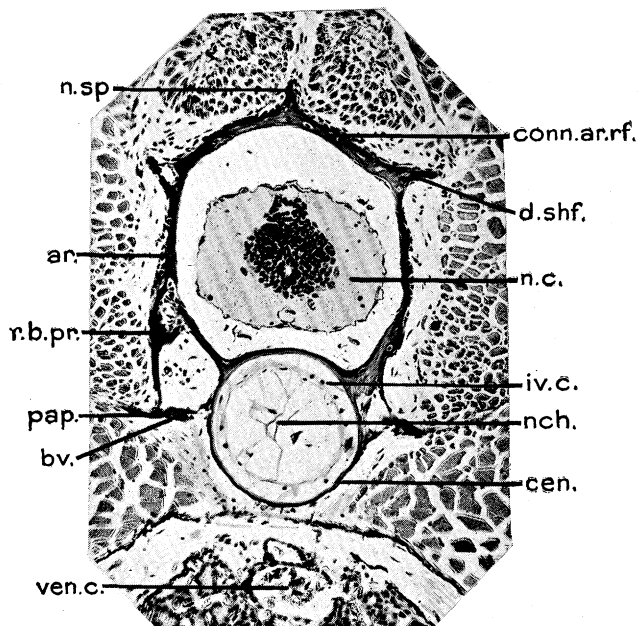
14.



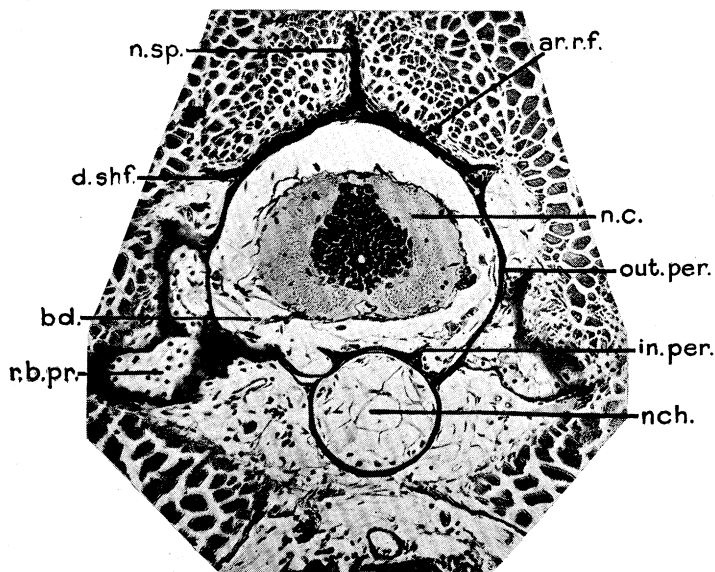
15.



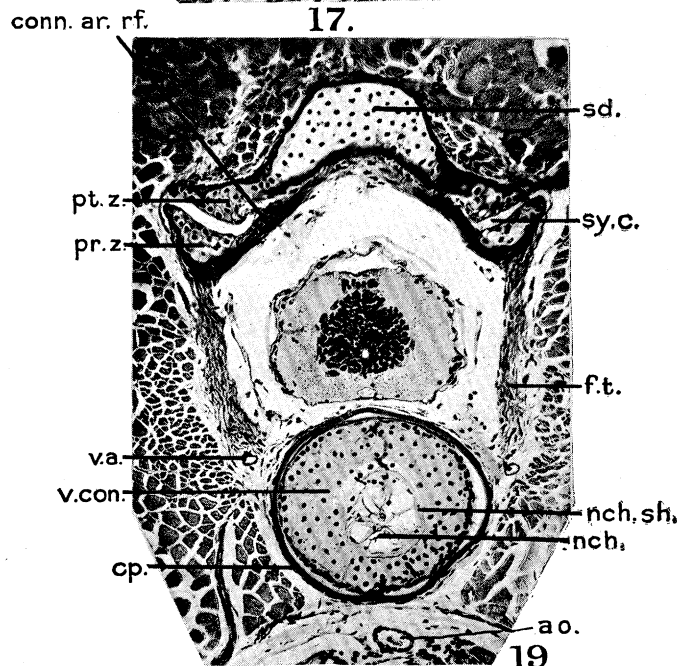
16.



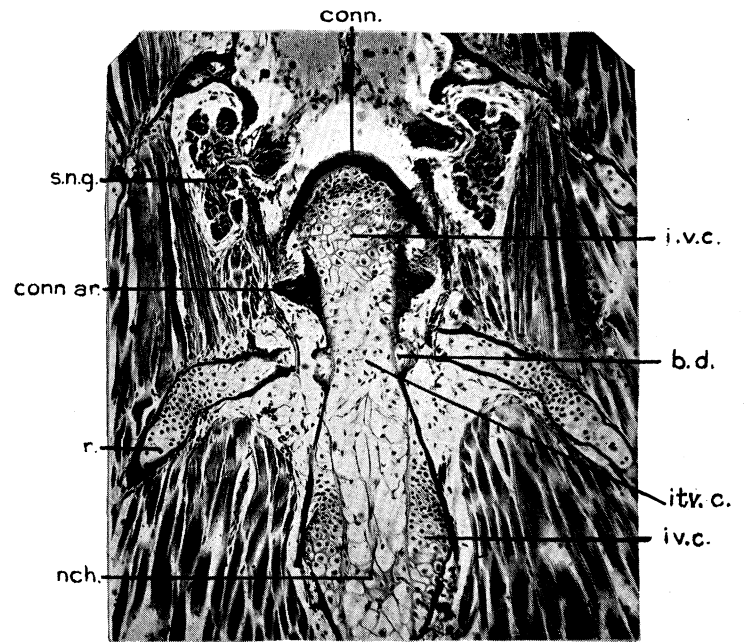
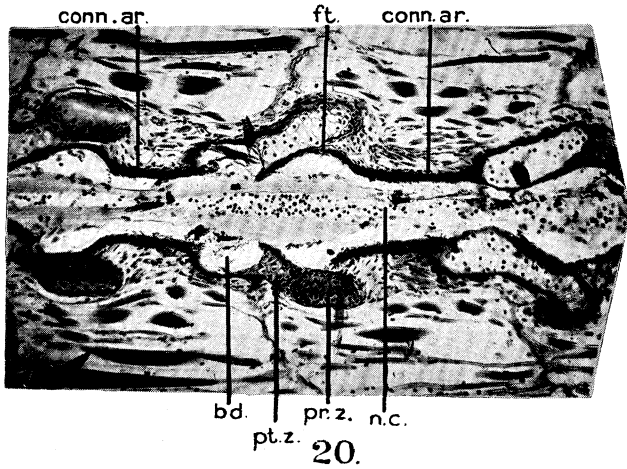
17.



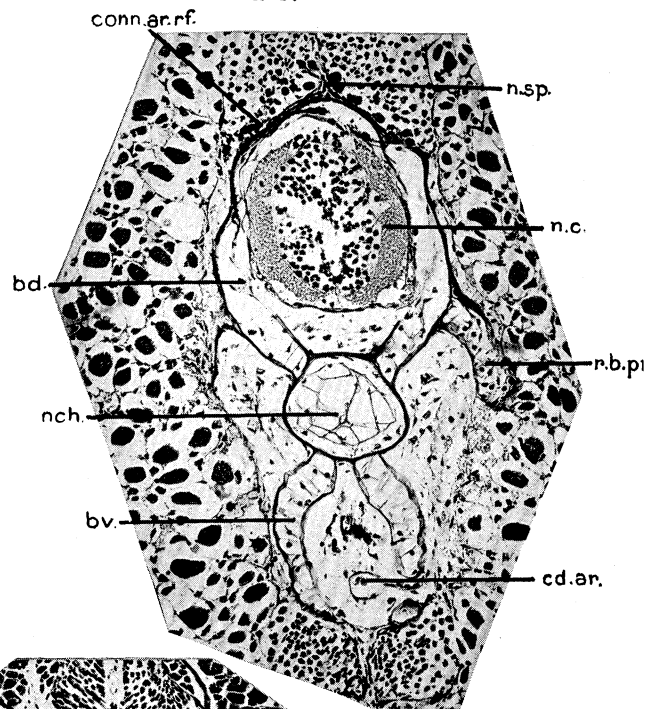
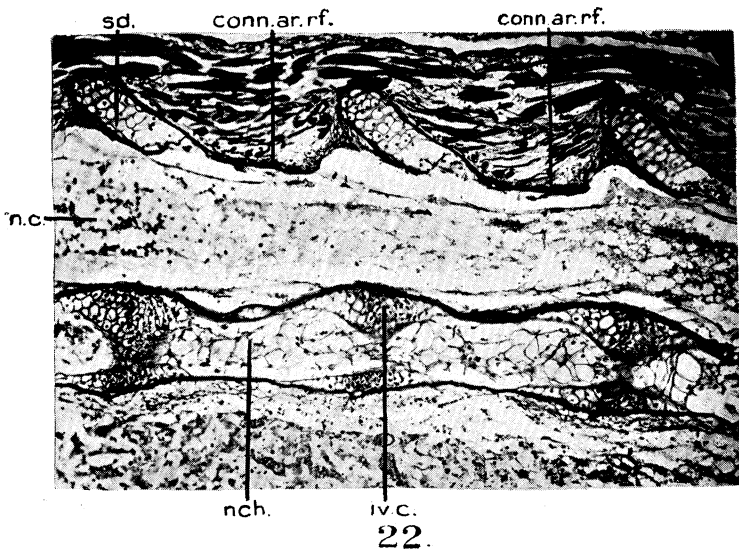
18.



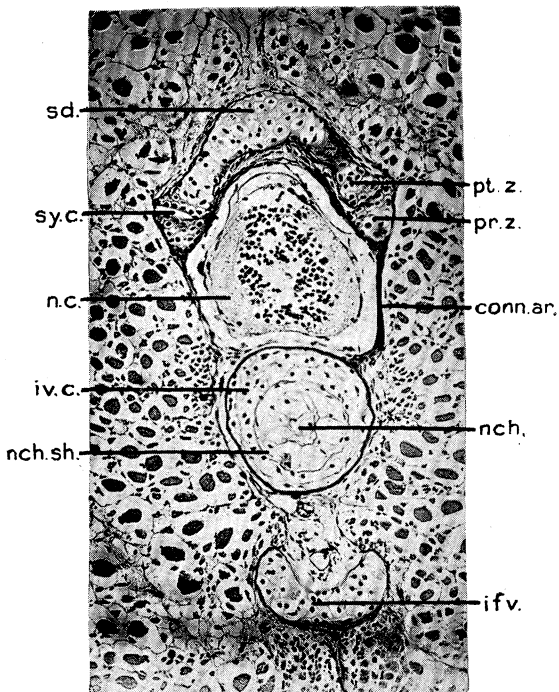
19.



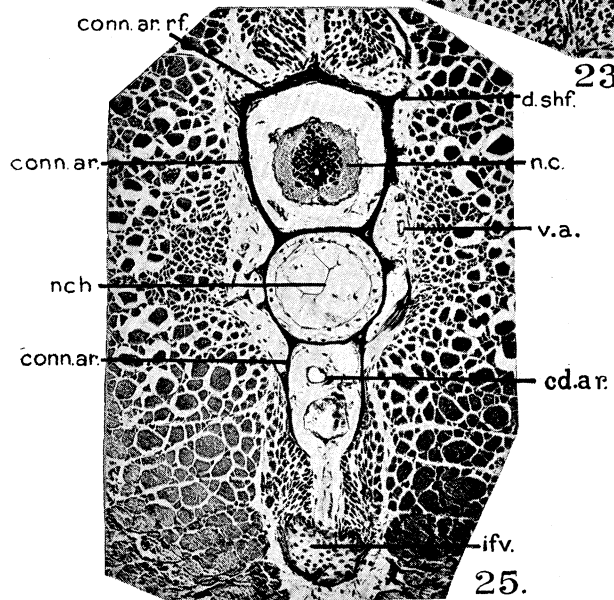
21.




23.



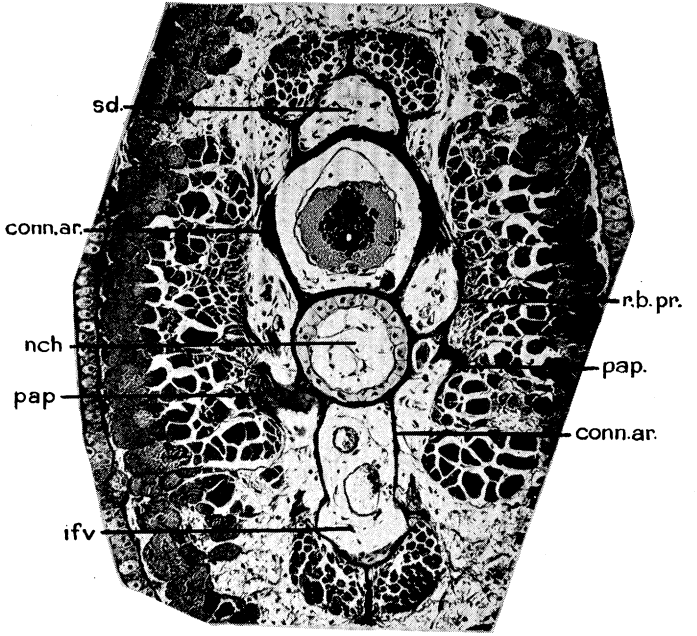
24.



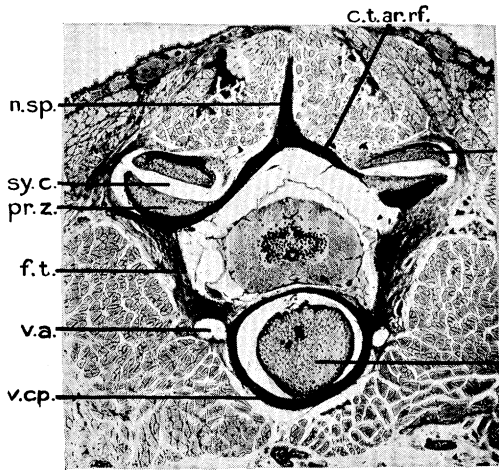
25.



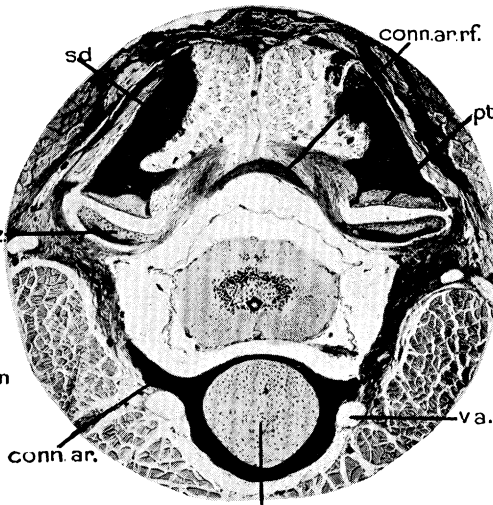
26.



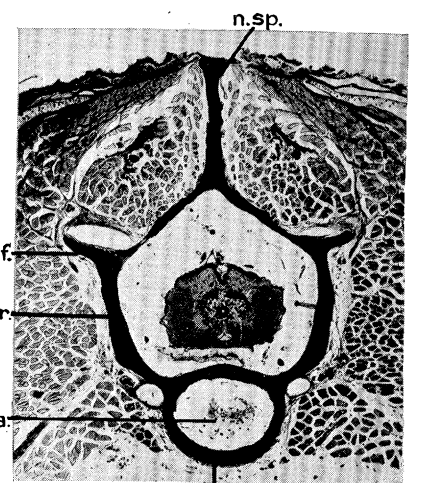
27.



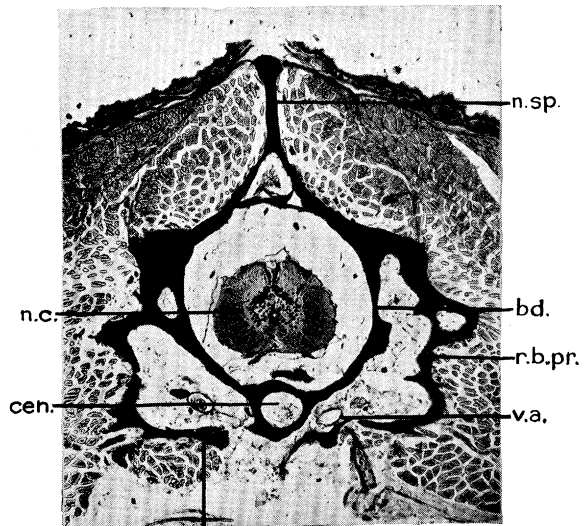
28.



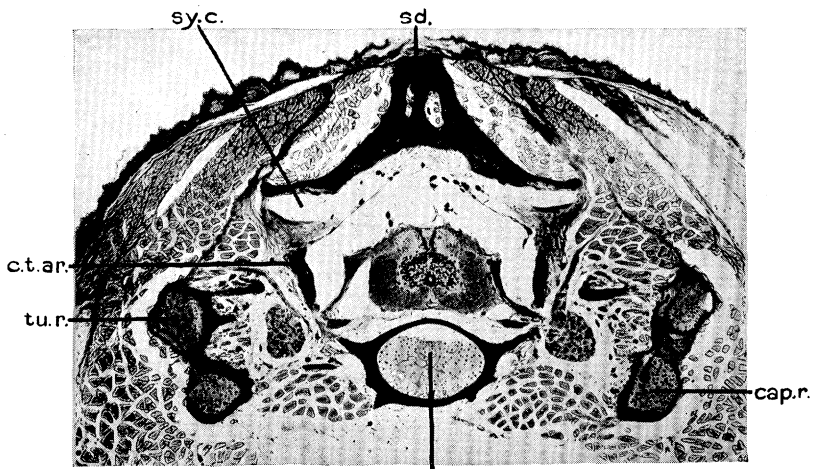
32.



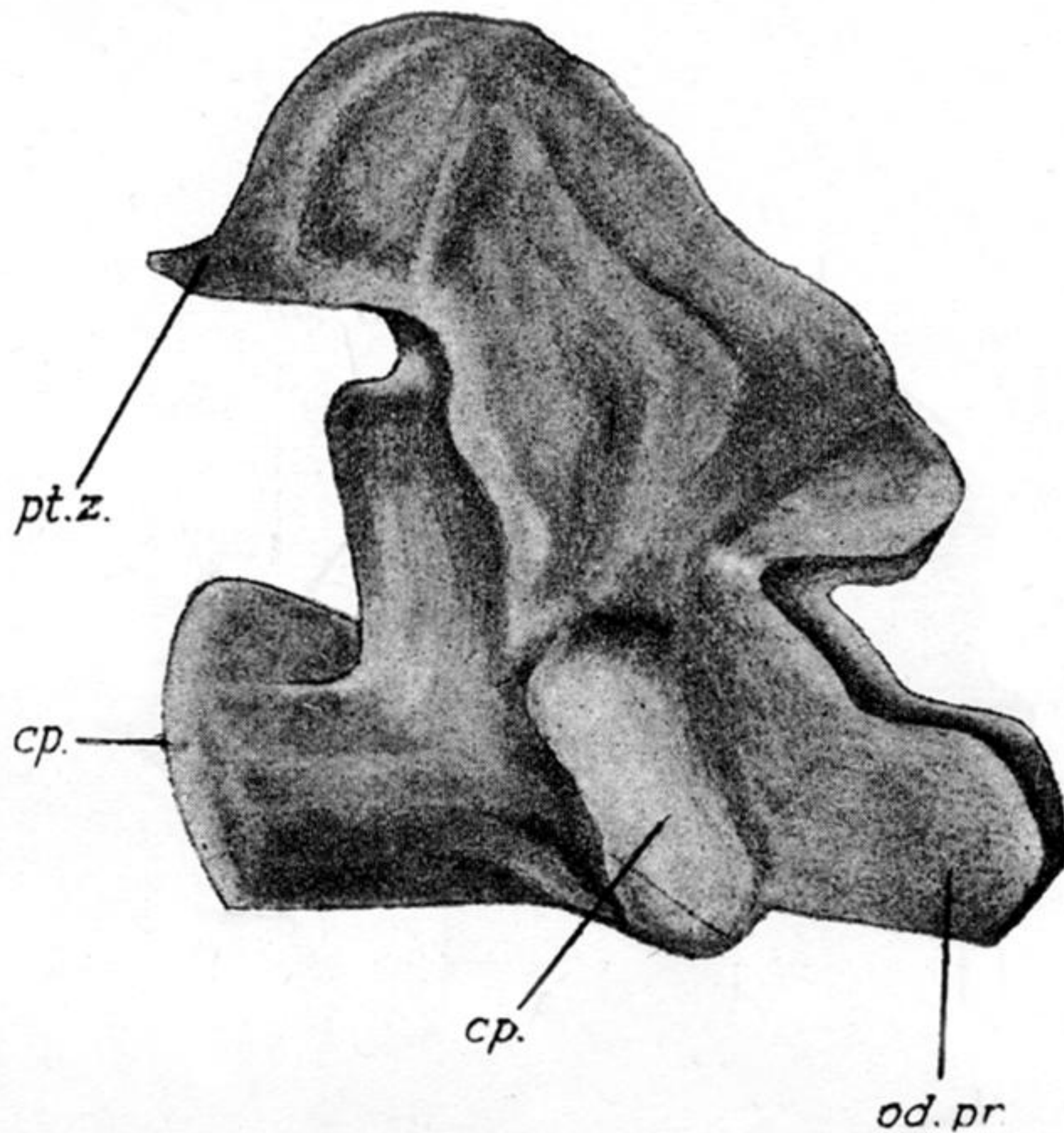
29.



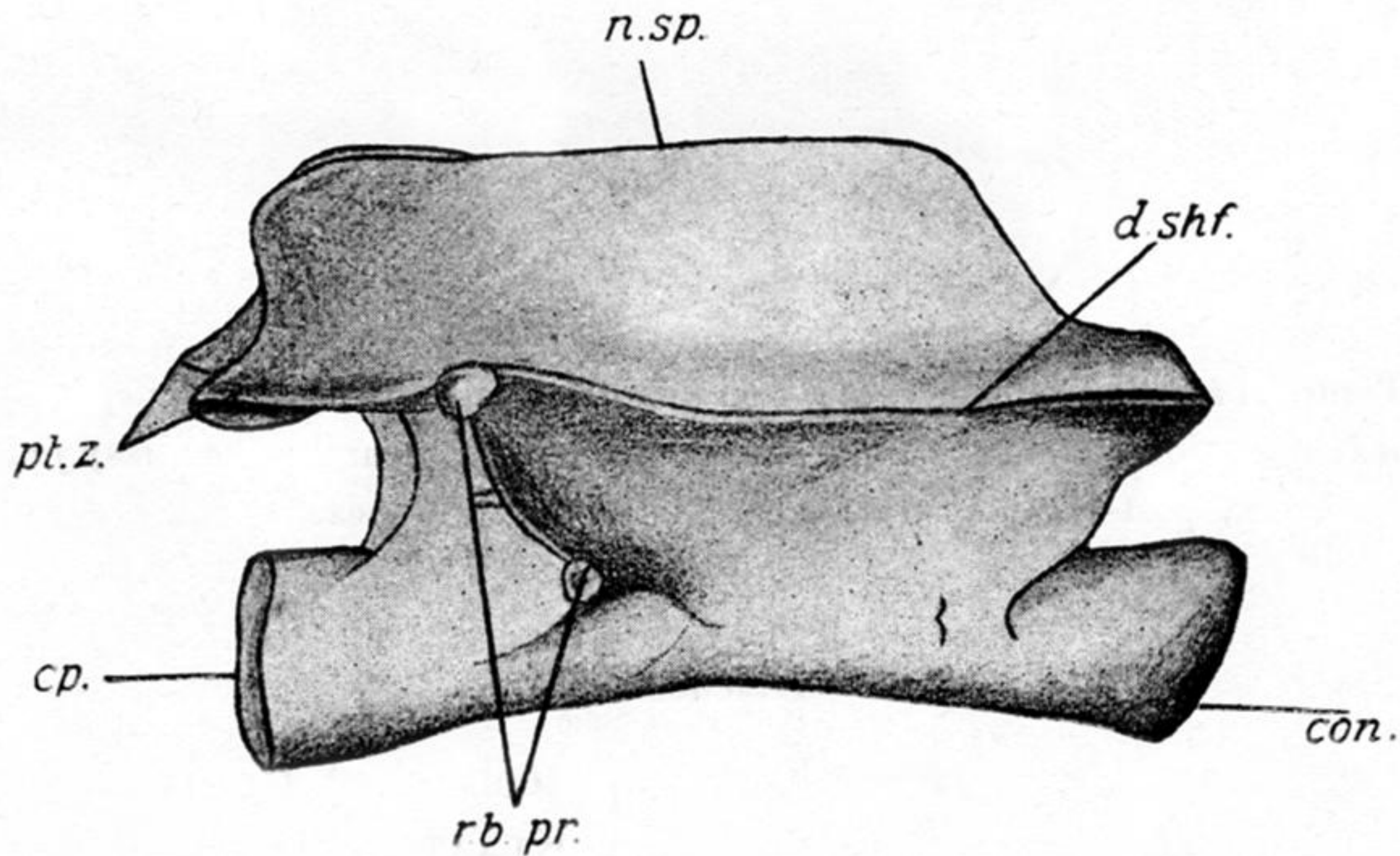
30.



31.



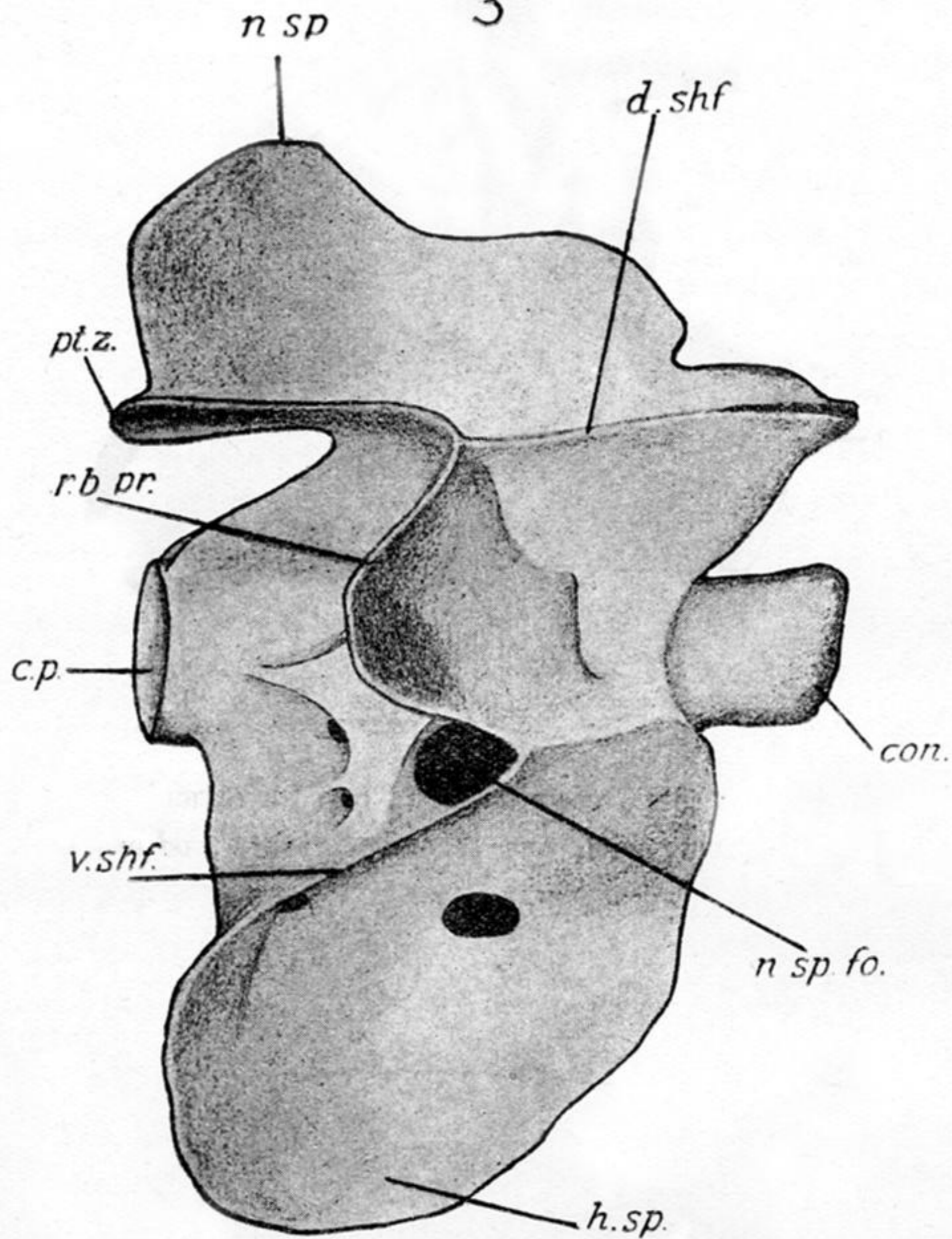
TEXT-FIG. 1.—Figure of an adult atlas (first) vertebra. *cp.*, cup for articulating with the condyle of the skull and also cup for articulating with the second vertebra; *od.pr.*, odontoid process; *pt.z.*, post-zygapophysis.



2

TEXT-FIG. 2.—Figure of an adult trunk vertebra. *con.*, condyle (ball) of the vertebra; *cp.*, cup for articulating with the next posterior vertebra; *d.shf.*, dorsal shelf; *n.sp.*, neural spine; *pt.z.*, post-zygapophysis; *rb.pr.*, bifurcated rib bearer.

3



TEXT-FIG. 3.—Figure of an adult tail vertebra. *con.*, condyle (ball) of the vertebra; *cp.*, cup for articulating with the next posterior vertebra; *d.shf.*, dorsal shelf; *n.sp.*, neural spine; *n.sp.fo.*, foramen for the spinal nerve; *pt.z.*, post-zygapophysis; *rb.pr.*, bifurcated rib bearer; *v.shf.*, ventral shelf; *h.sp.*, hæmal spine.

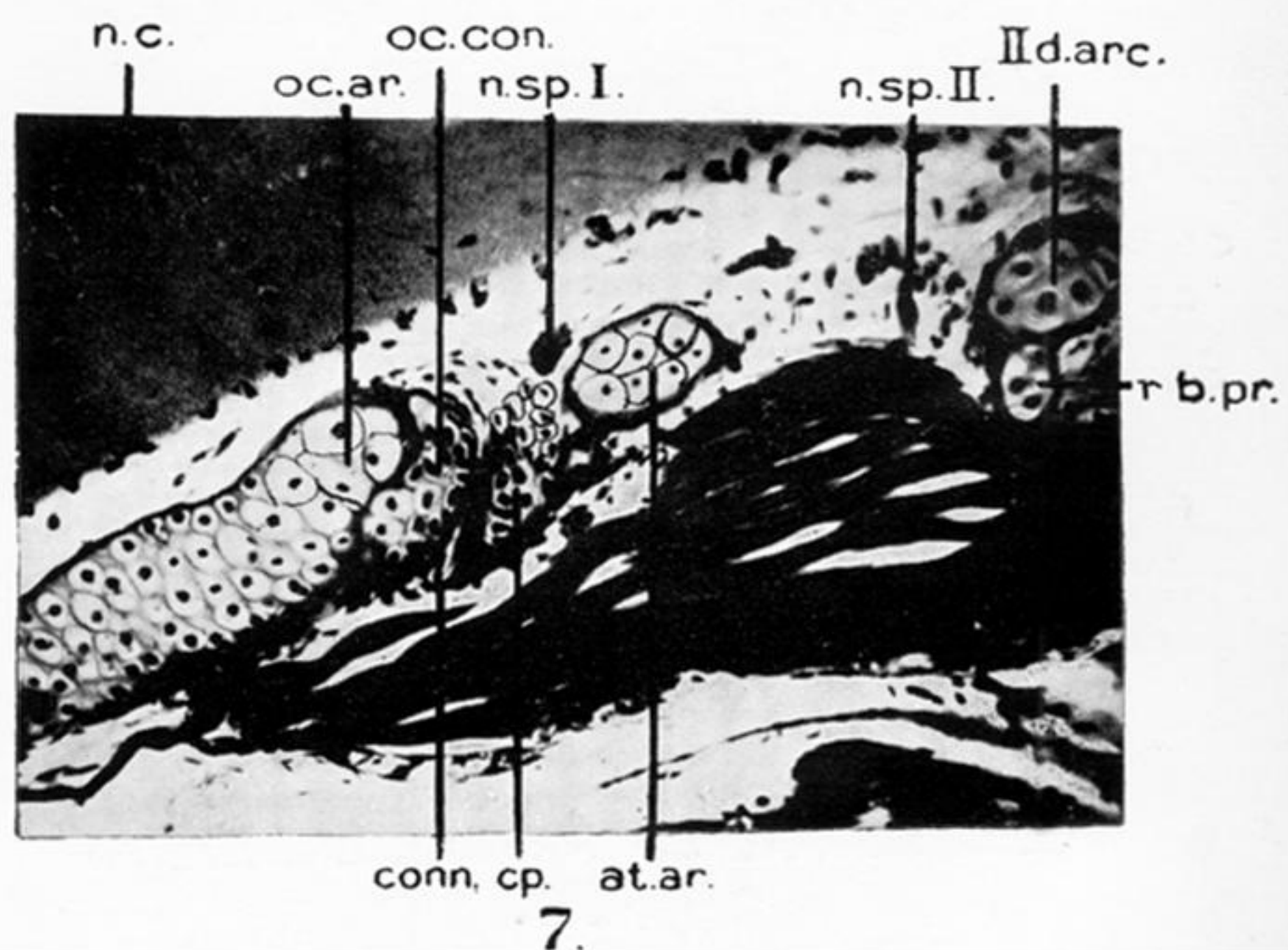
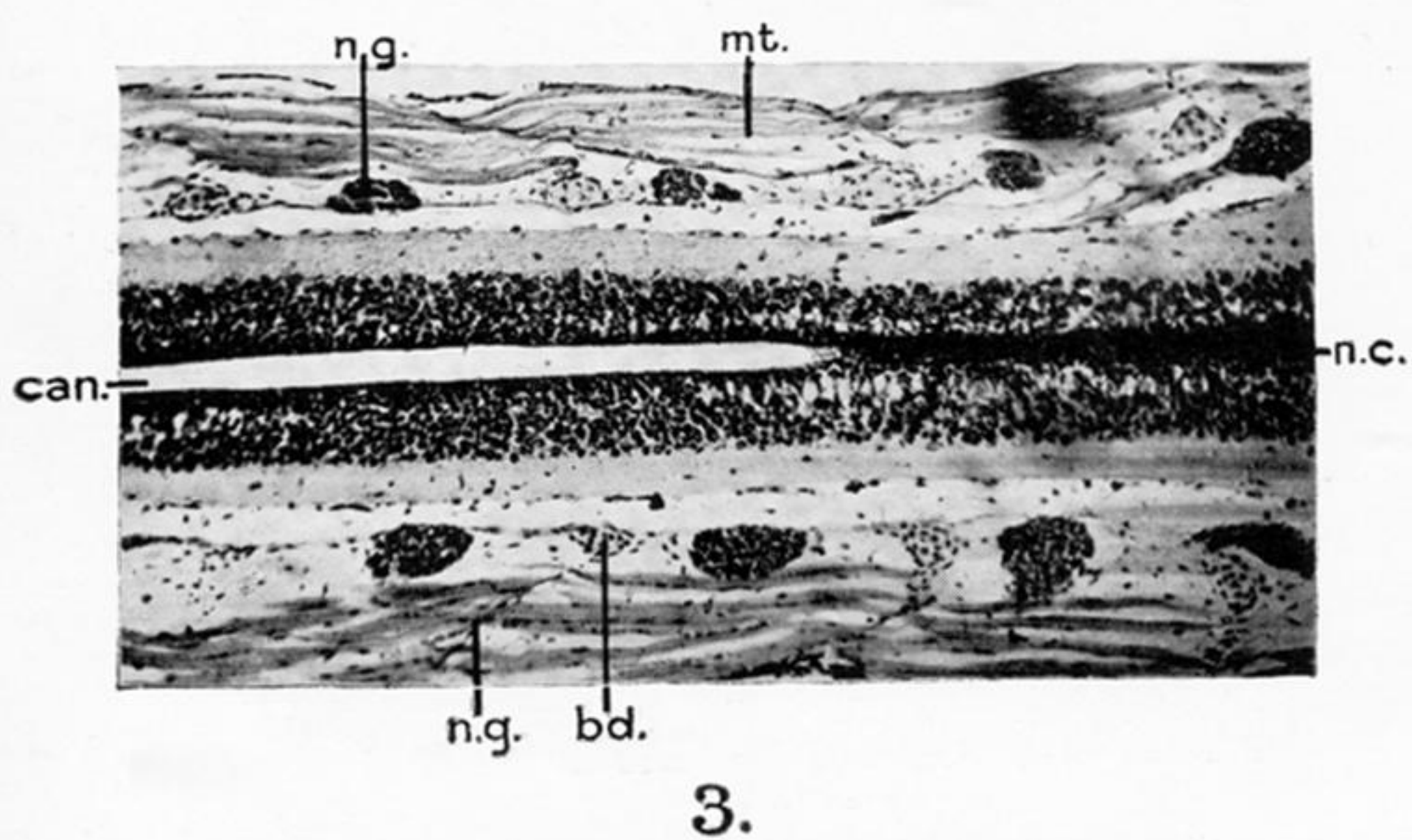
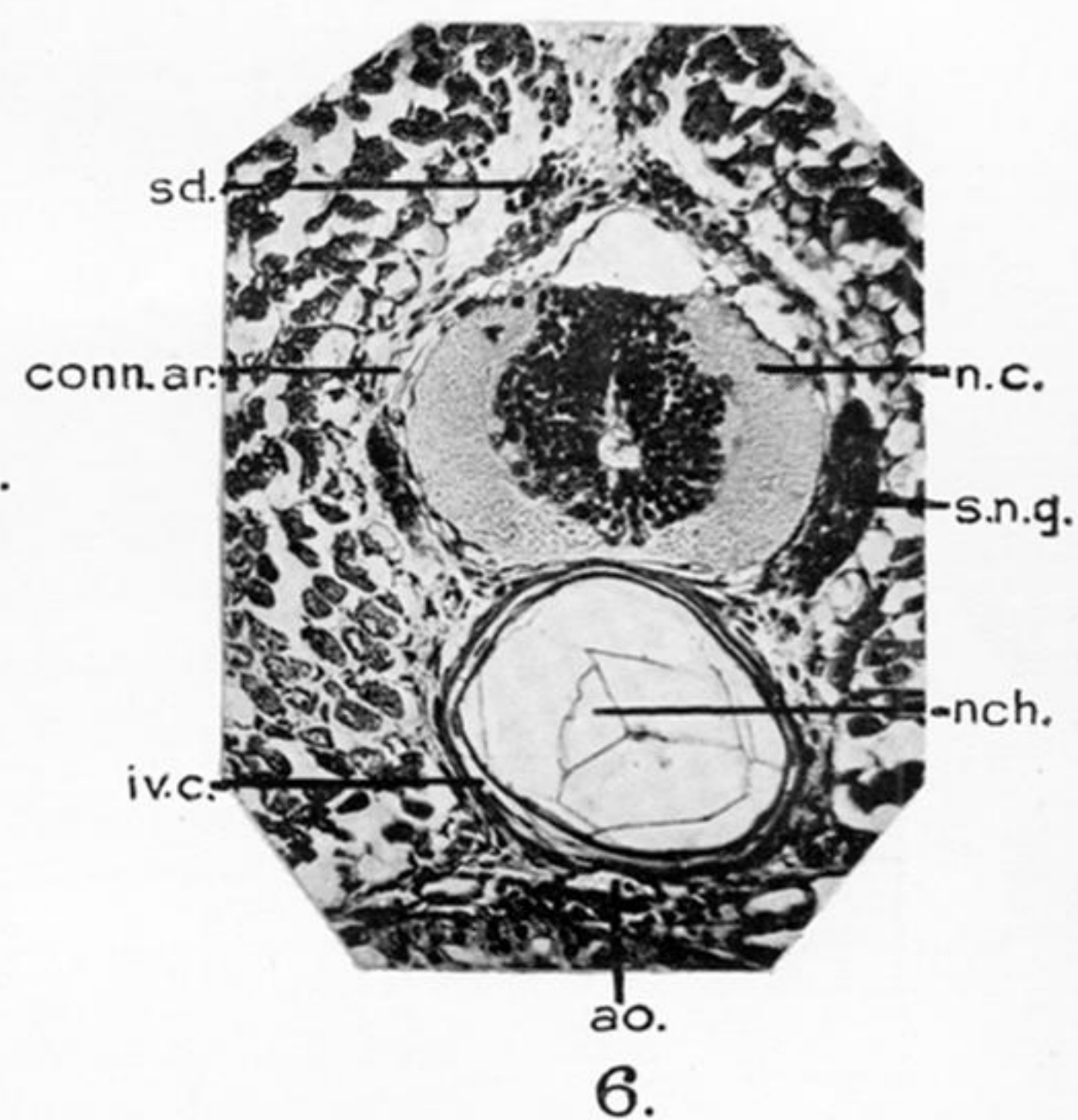
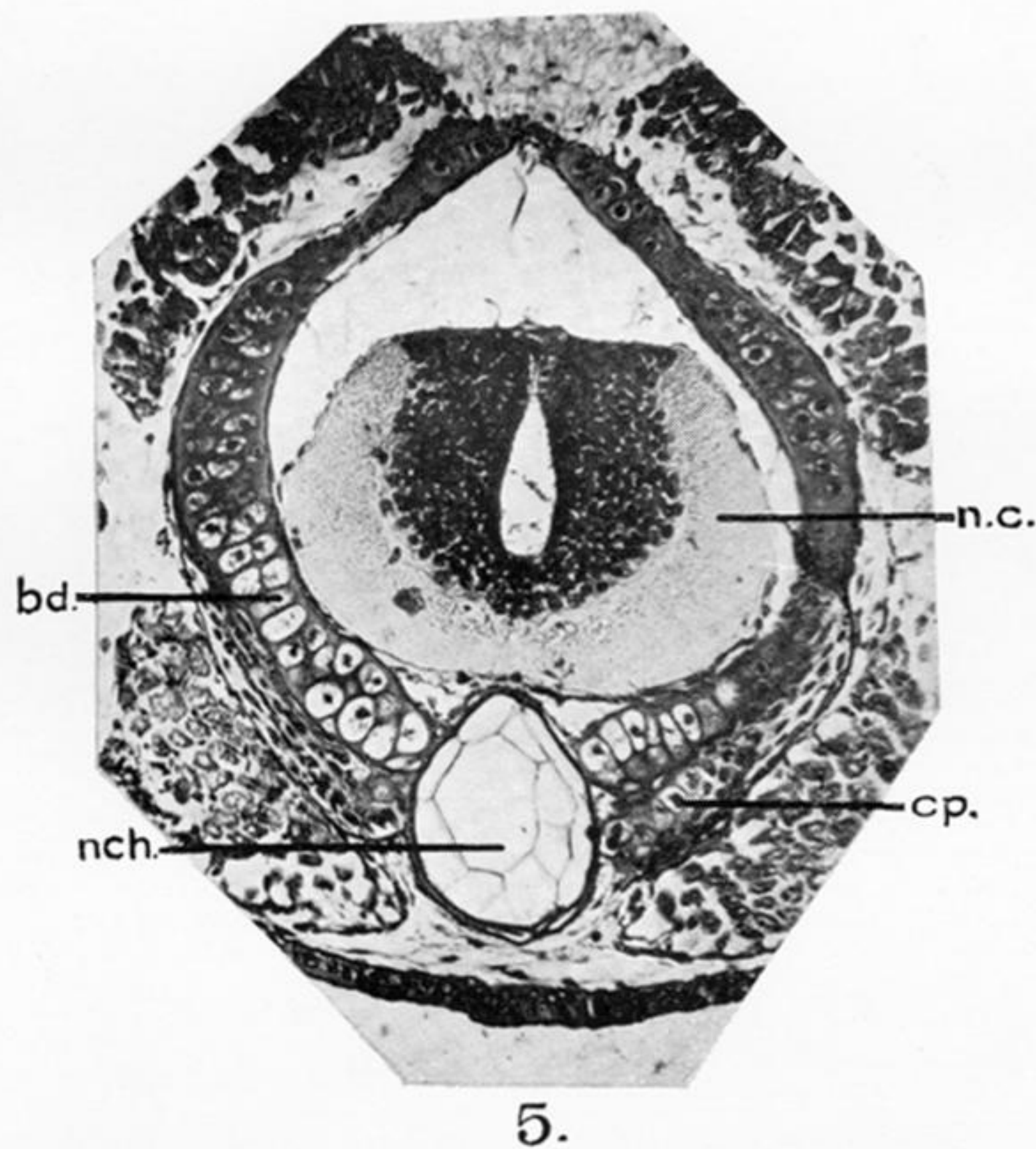
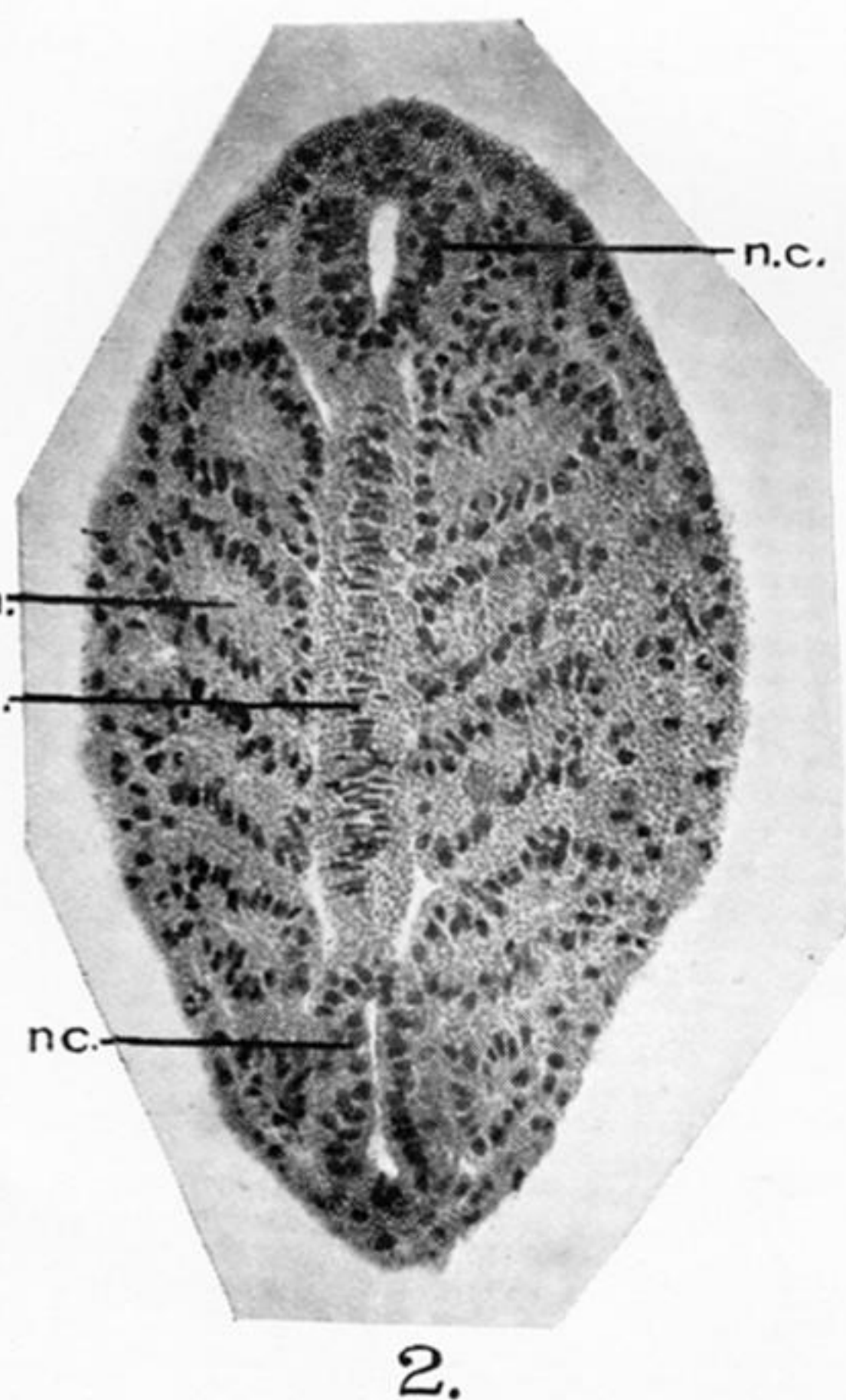
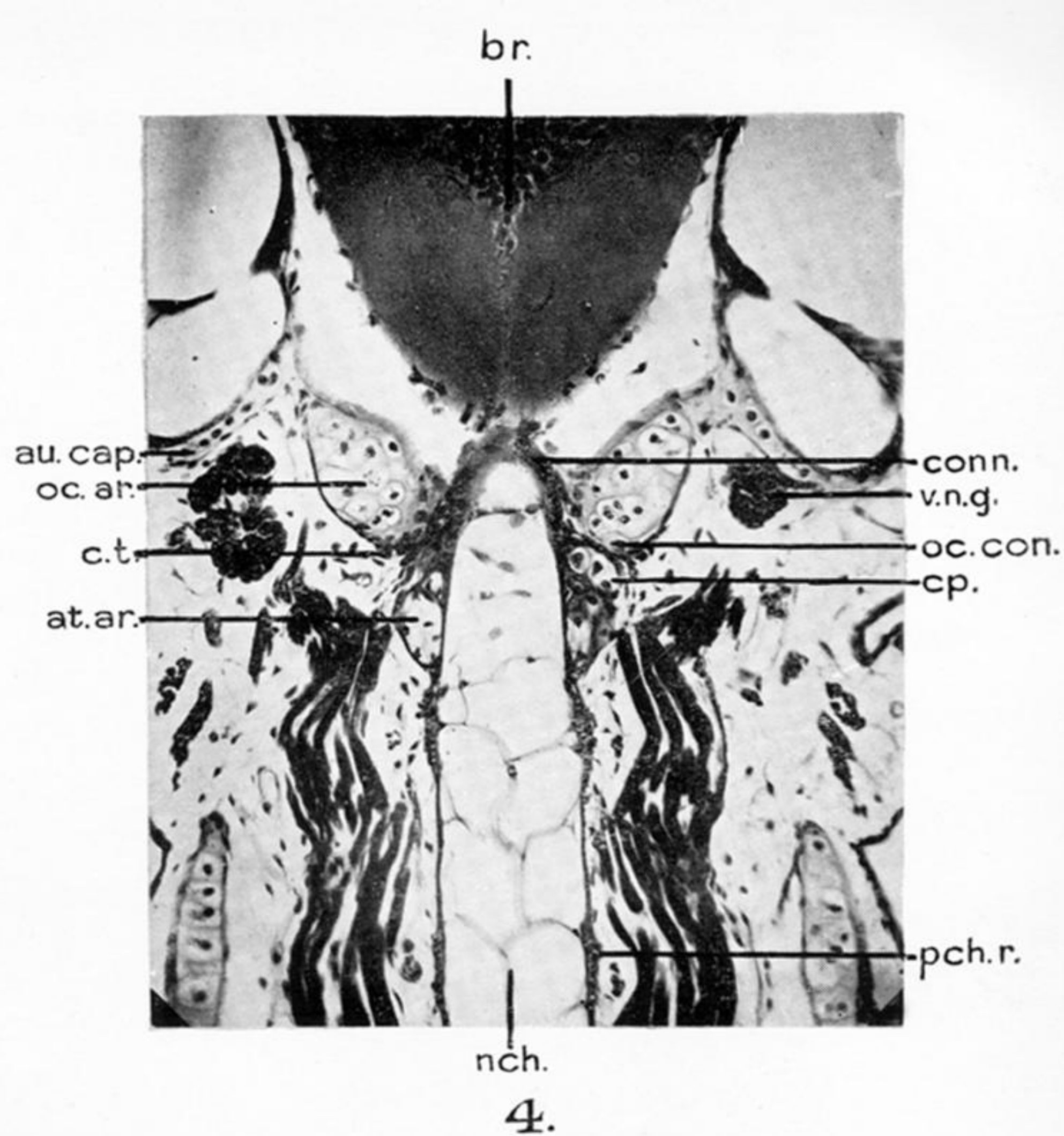
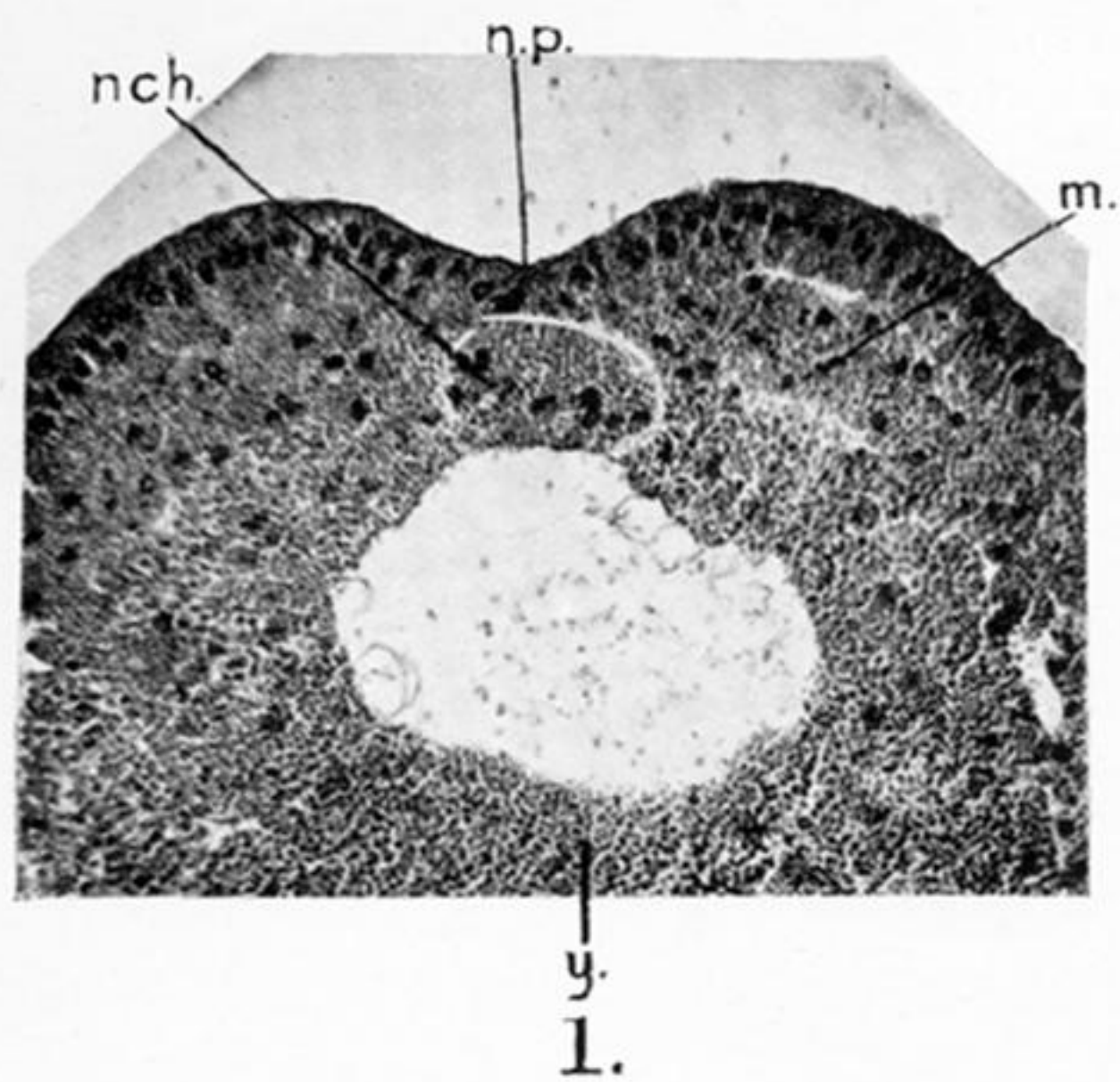


PLATE 44.

FIG. 1.—Transverse section through the stage A. *m.*, mesoderm; *nch.*, notochord; *n.p.*, neural plate; *y.*, yolky endoderm cells.

FIG. 2.—Frontal section through the stage B. *nch.*, notochord; *n.c.*, neural cord; *sm.*, somite.

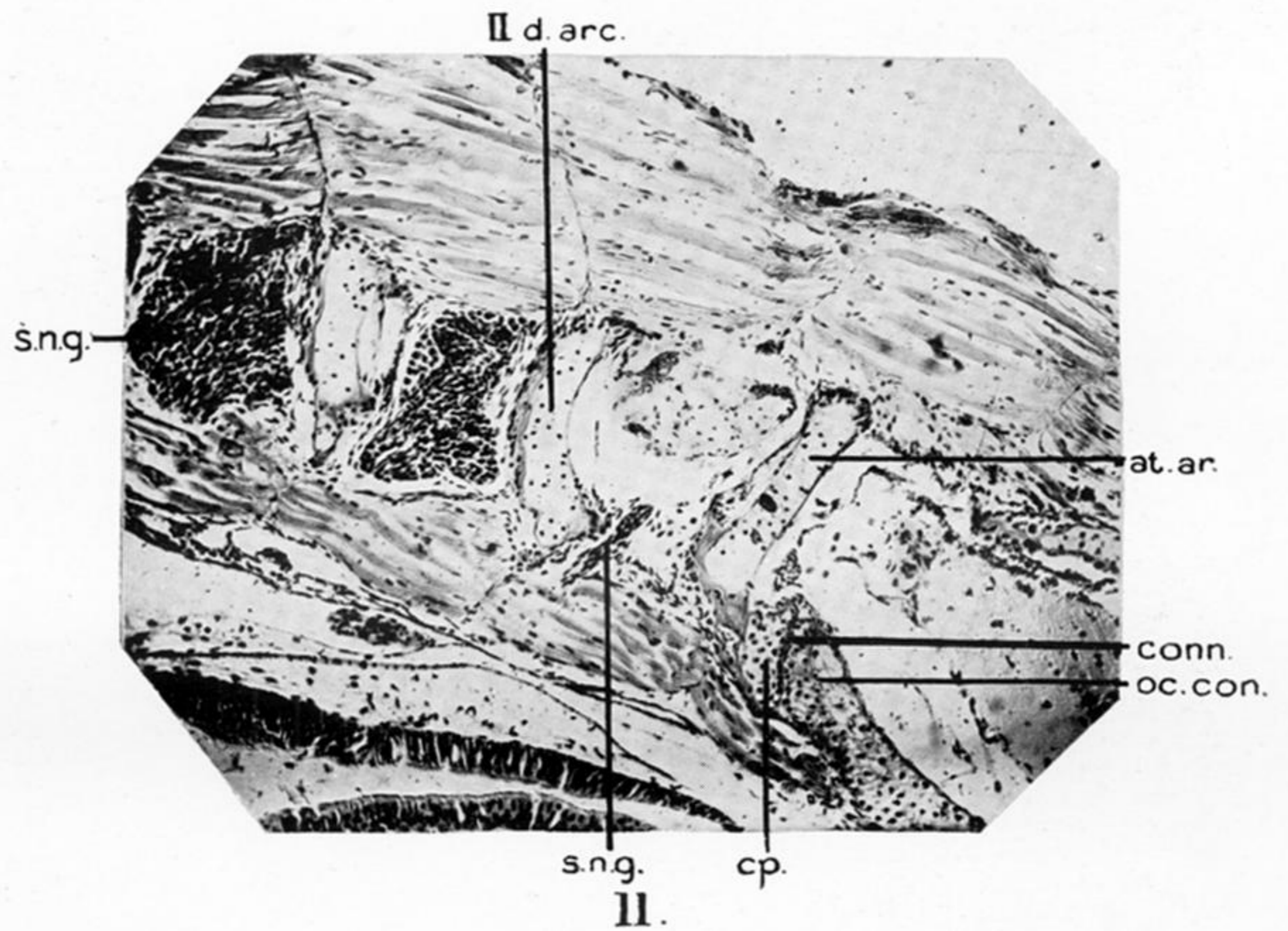
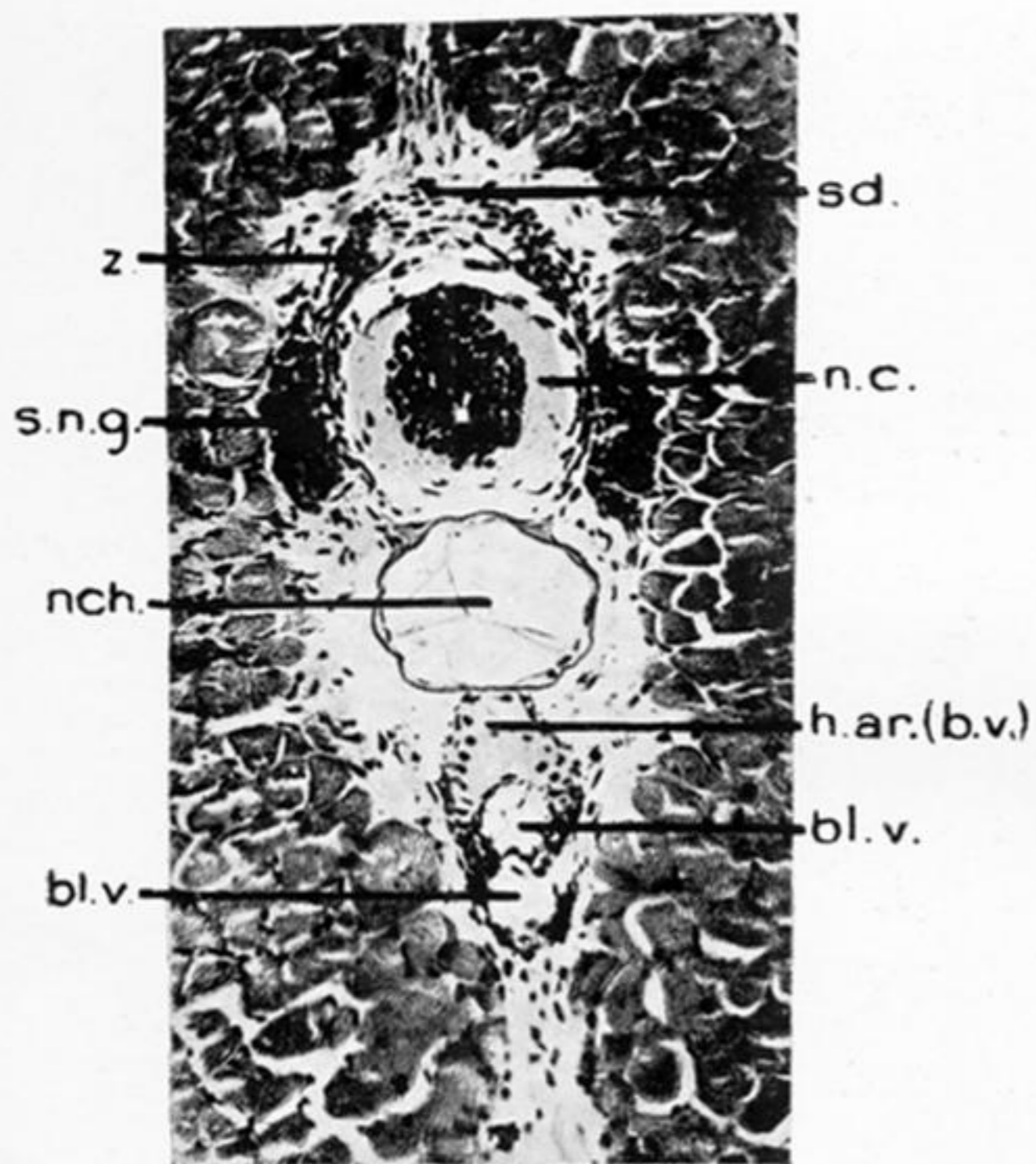
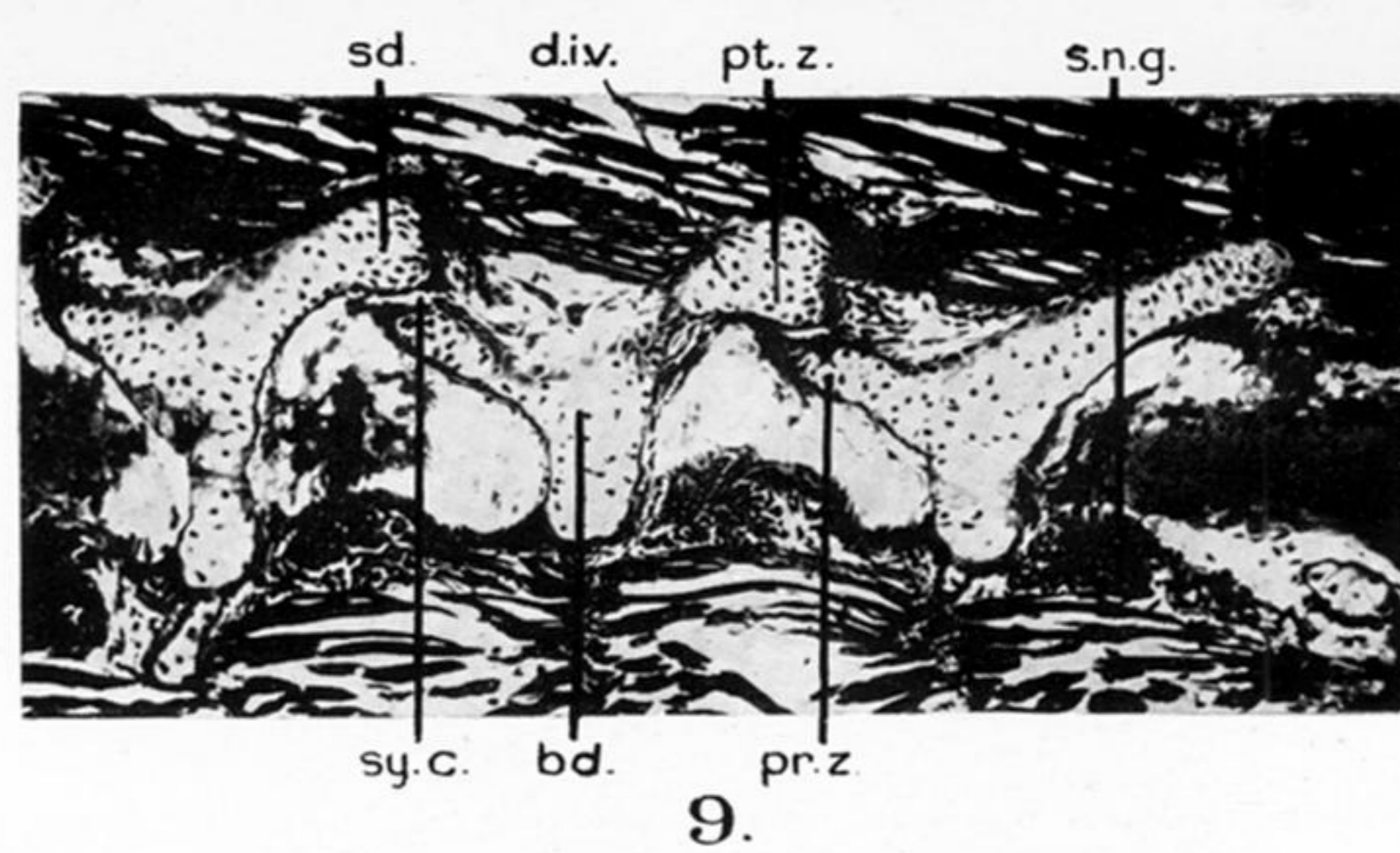
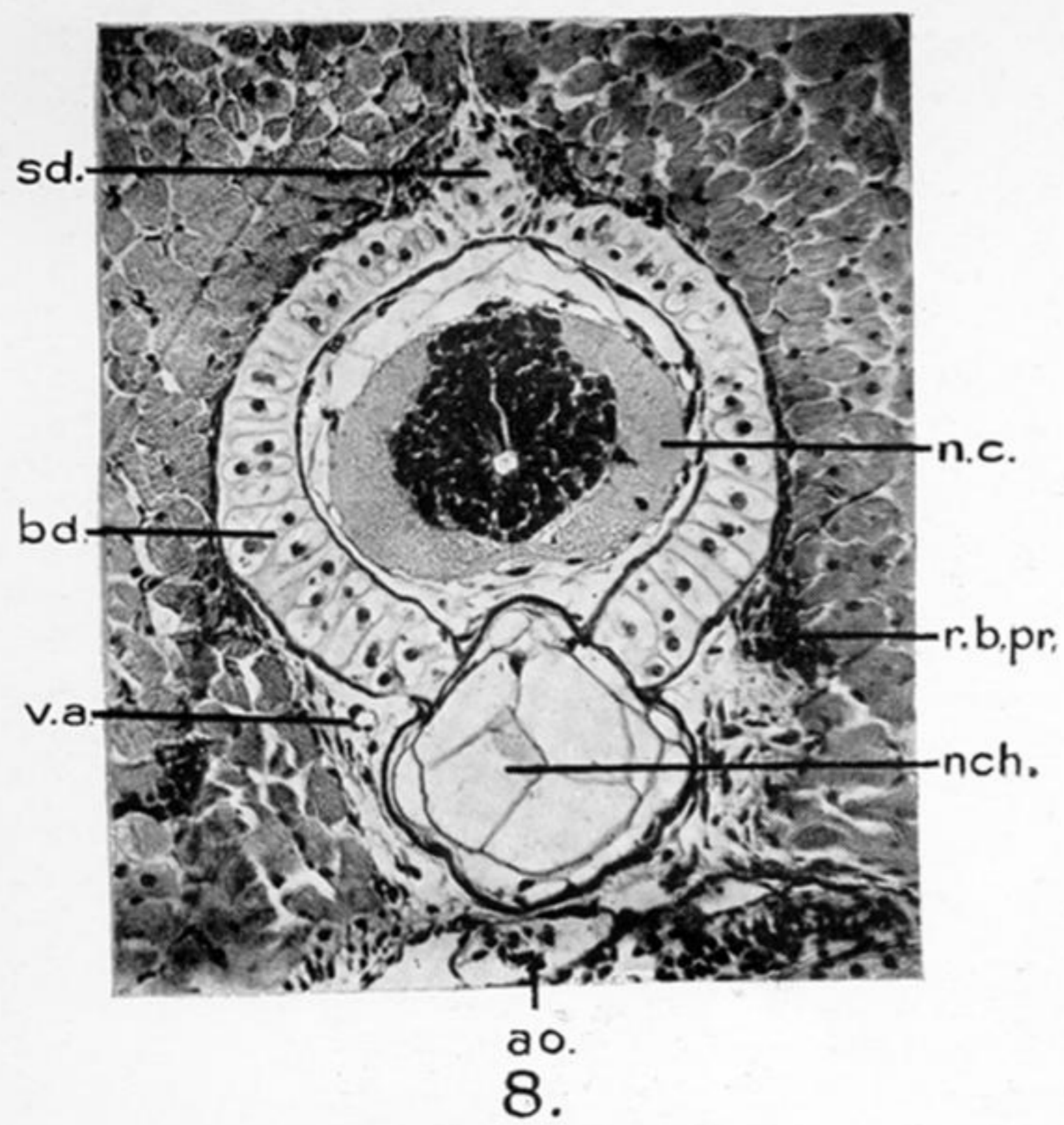
FIG. 3.—Frontal section through the 8 mm. stage. *Bd.*, basidorsal; *can.*, central canal of the nerve cord; *mt.*, myotome; *n.c.*, neural cord; *n.g.*, nerve ganglion.

FIG. 4.—Frontal section through 12 mm. stage. *at.ar.*, atlas arch; *au.cap.*, auditory capsule; *br.*, brain; *cp.*, cup; *conn.*, connective tissue; *nch.*, notochord; *oc.ar.*, occipital arch; *oc.con.*, occipital condyle; *pch.r.*, perichordal ring.

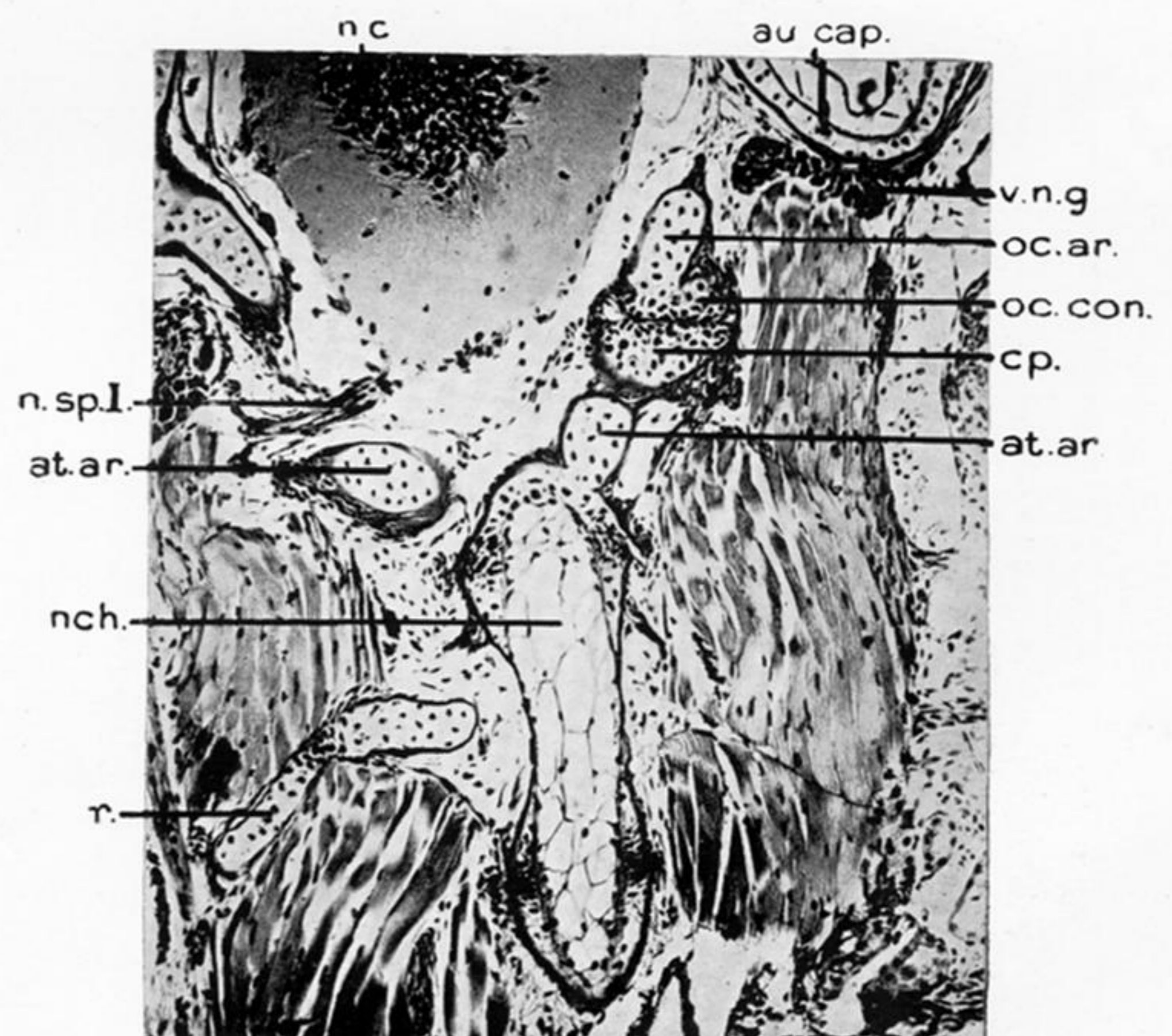
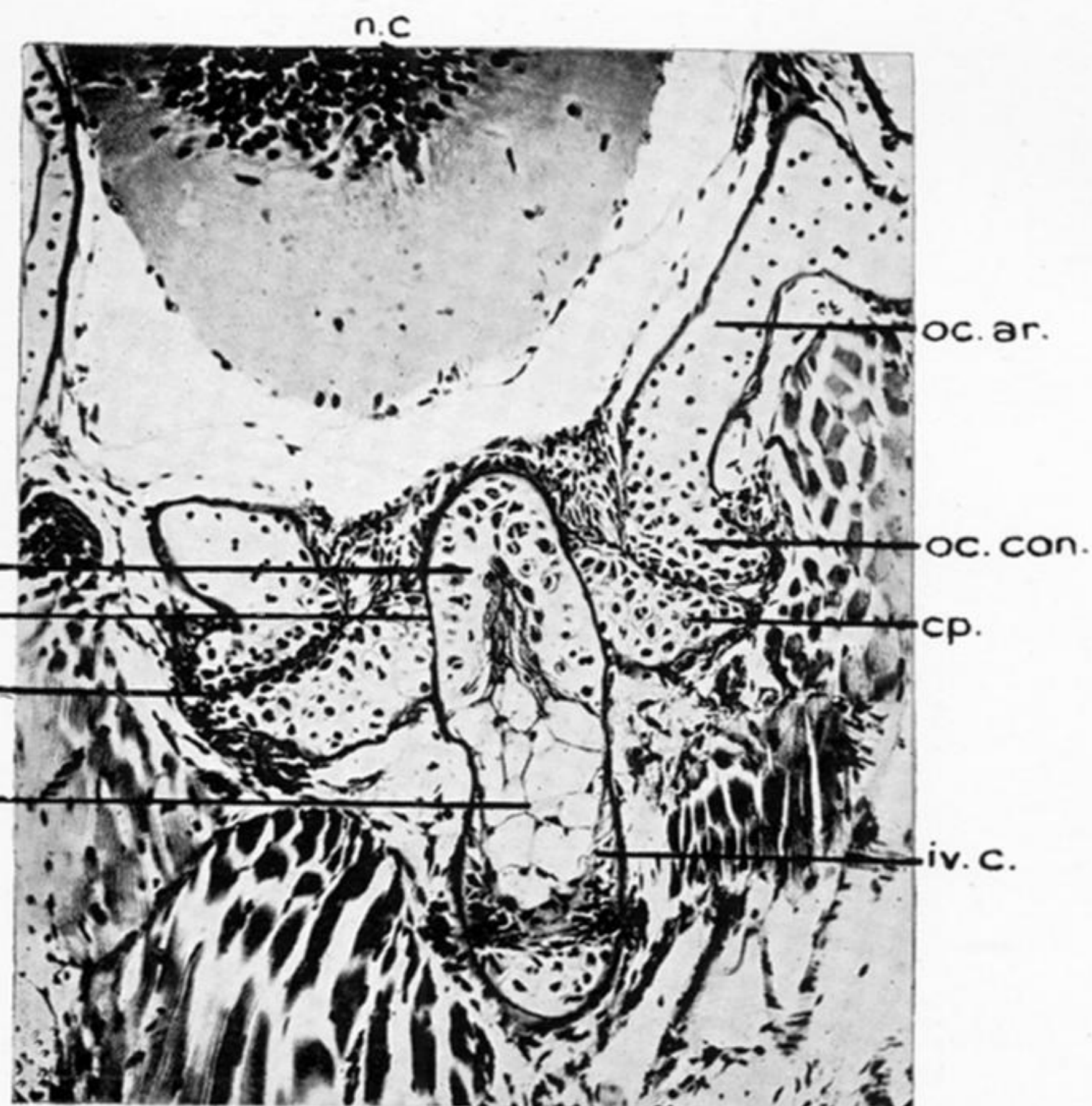
FIG. 5.—Transverse section through the atlas vertebra at 15 mm. stage. *bd.*, basidorsal; *cp.*, cup of the atlas vertebra; *nch.*, notochord; *n.c.*, neural cord.

FIG. 6.—Transverse section through the interspace between two consecutive cartilaginous dorsal arcualia at 15 mm. stage. *ao.*, aorta; *conn.ar.*, connective tissue arch; *iv.c.*, intervertebral cartilage; *nch.*, notochord; *n.c.*, neural canal; *sd.*, supradorsal; *s.n.g.*, spinal nerve ganglion.

FIG. 7.—Sagittal section through the occipital and the atlas regions at 20 mm. stage. *at.ar.*, atlas arch; *cp.*, cup; *conn.*, connective tissue which forms the synovial cavity; *n.c.*, neural cord; *n.sp.I.*, nerve spinalis I (sub-occipital); *n.sp.II.*, nerve spinalis II (hypoglossal); *II d.arc.*, second dorsal arch; *oc.ar.*, occipital arch; *oc.con.*, occipital condyle; *r.b.pr.*, rib bearing process.



10.



12.

13.

PLATE 45.

FIG. 8.—Transverse section through the trunk vertebra at 20 mm. stage. *ao.*, aorta; *bd.*, basidorsal; *n.c.*, neural cord; *nch.*, notochord; *r.b.pr.*, rib bearing process; *sd.*, supradorsal; *v.a.*, vertebral artery.

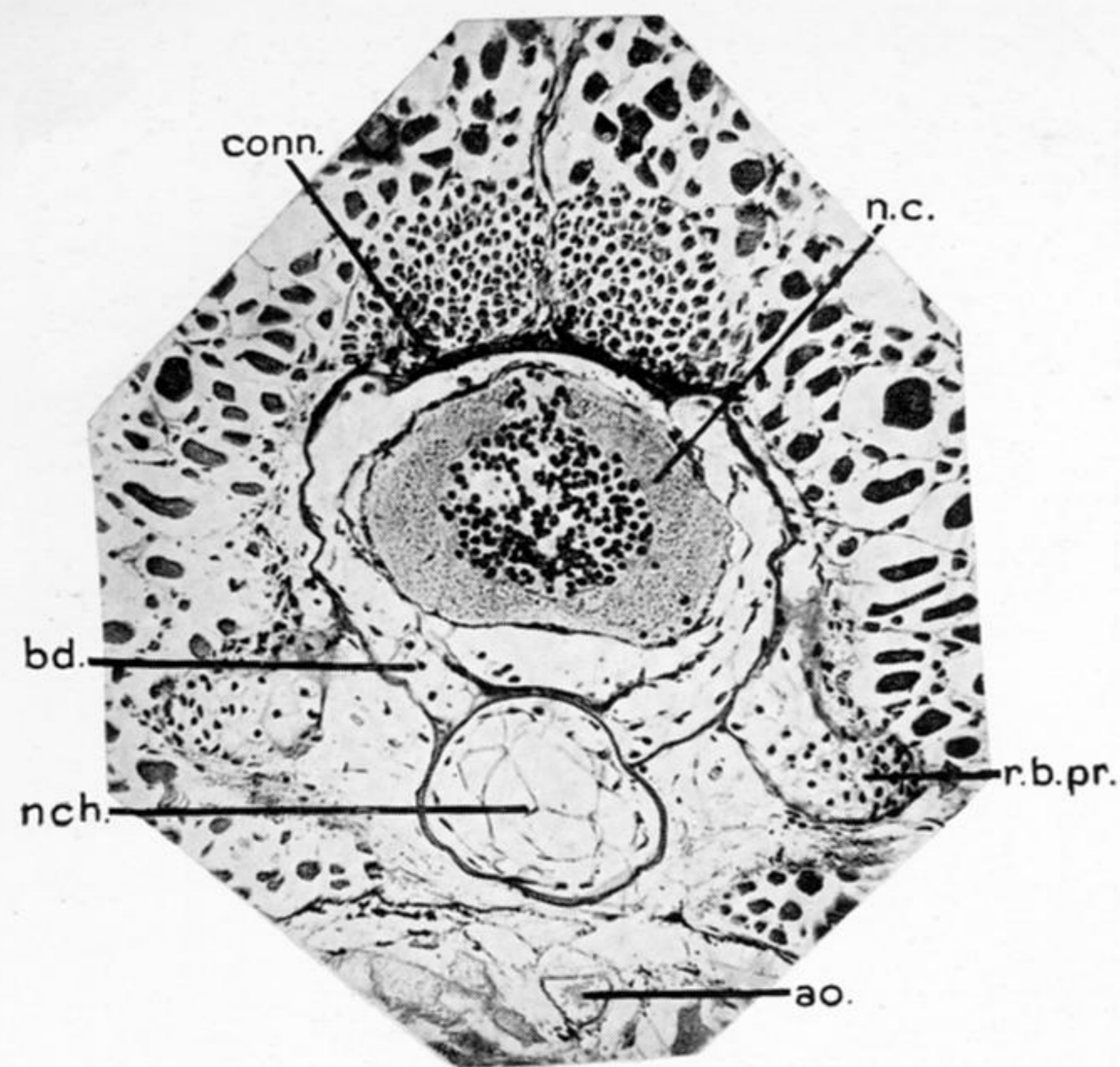
FIG. 9.—Sagittal section through a few neural arches at 20 mm. stage. *bd.*, basidorsal; *pr.z.*, prezygapophysis; *pt.z.*, post-zygapophysis; *sd.*, supradorsal; *sy.c.*, synovial cavity; *s.n.g.*, spinal nerve ganglion.

FIG. 10.—Transverse section through the tail region at 20 mm. stage. *bl.v.*, blood vessel; *h.ar.*, haemal arch; *n.c.*, neural cord; *nch.*, notochord; *sd.*, supradorsal; *s.n.g.*, spinal nerve ganglion; *z.*, zygapophysis.

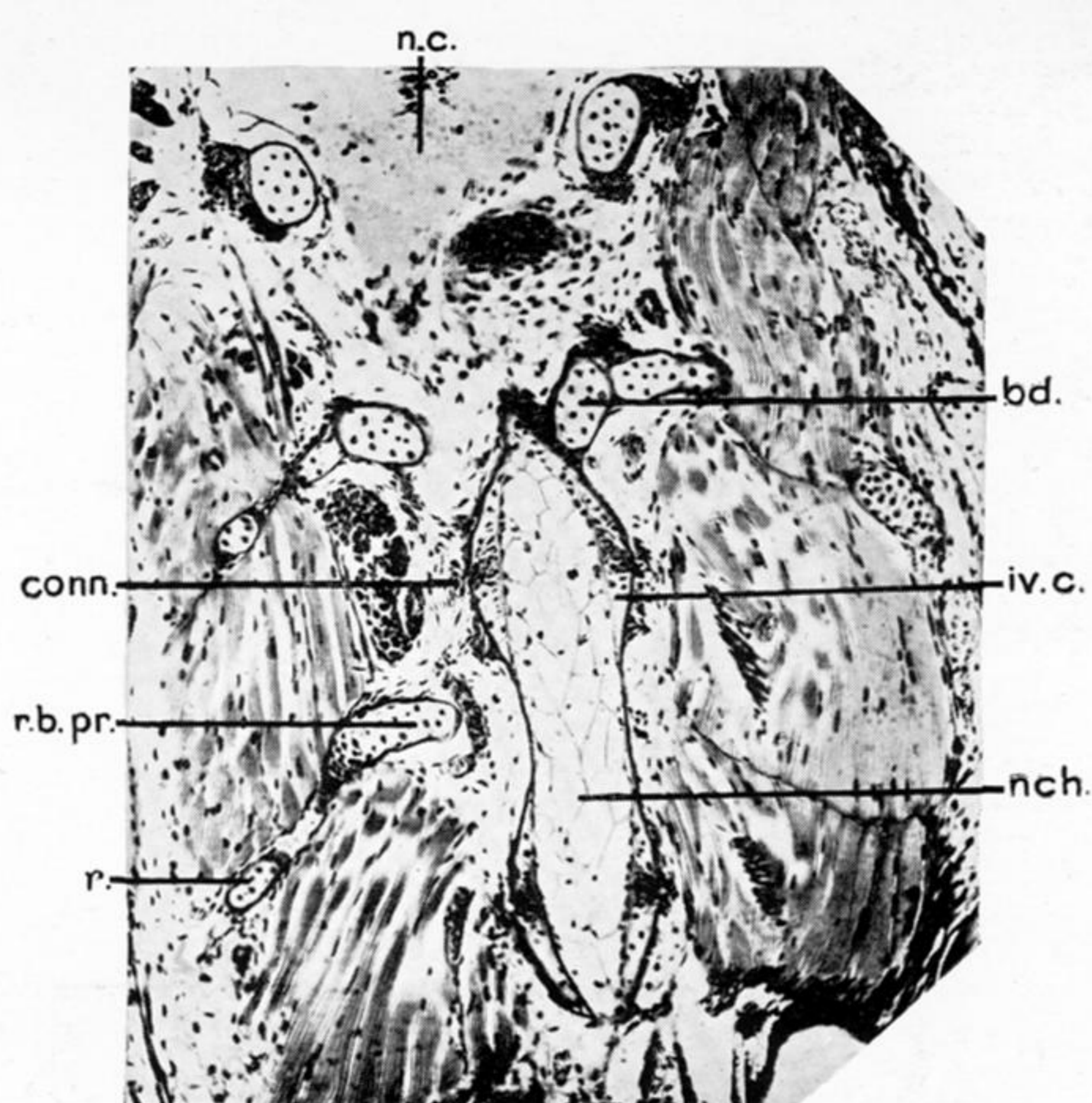
FIG. 11.—Sagittal section through the atlas region at 25 mm. stage. *at.ar.*, atlas arch; *cp.*, cup; *conn.*, connective tissue which forms the synovial cavity; *oc.con.*, occipital condyle; *s.n.g.*, spinal nerve ganglion.

FIG. 12.—Frontal section through the occipital and the atlas regions at 25 mm. stage. *cen.*, centrum; *conn.*, connective tissue which forms the synovial cavity; *cp.*, cup; *iv.c.*, intervertebral cartilage; *nch.*, notochord; *oc.ar.*, occipital arch; *oc.con.*, occipital condyle; *od.pr.*, odontoid process.

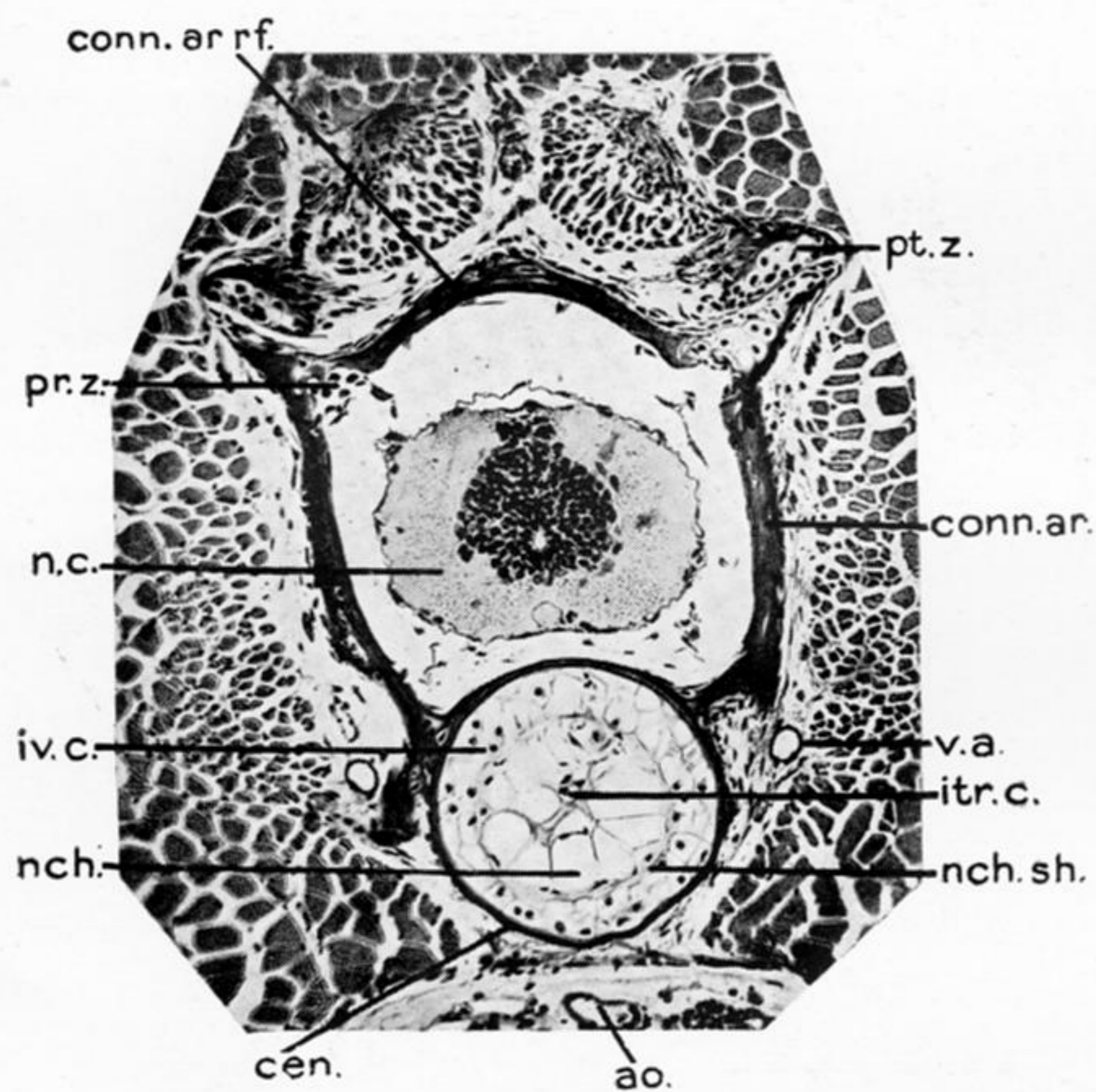
FIG. 13.—Frontal section through the same specimen as that of fig. 12, more dorsally. *at.ar.*, atlas arch; *au.cap.*, auditory capsule; *cp.*, cup; *nch.*, notochord; *n.c.*, neural cord; *n.sp.I.*, nerve spinalis I; *oc.ar.*, occipital arch; *oc.con.*, occipital condyle; *r.*, rib; *v.n.g.*, vagus nerve ganglion.



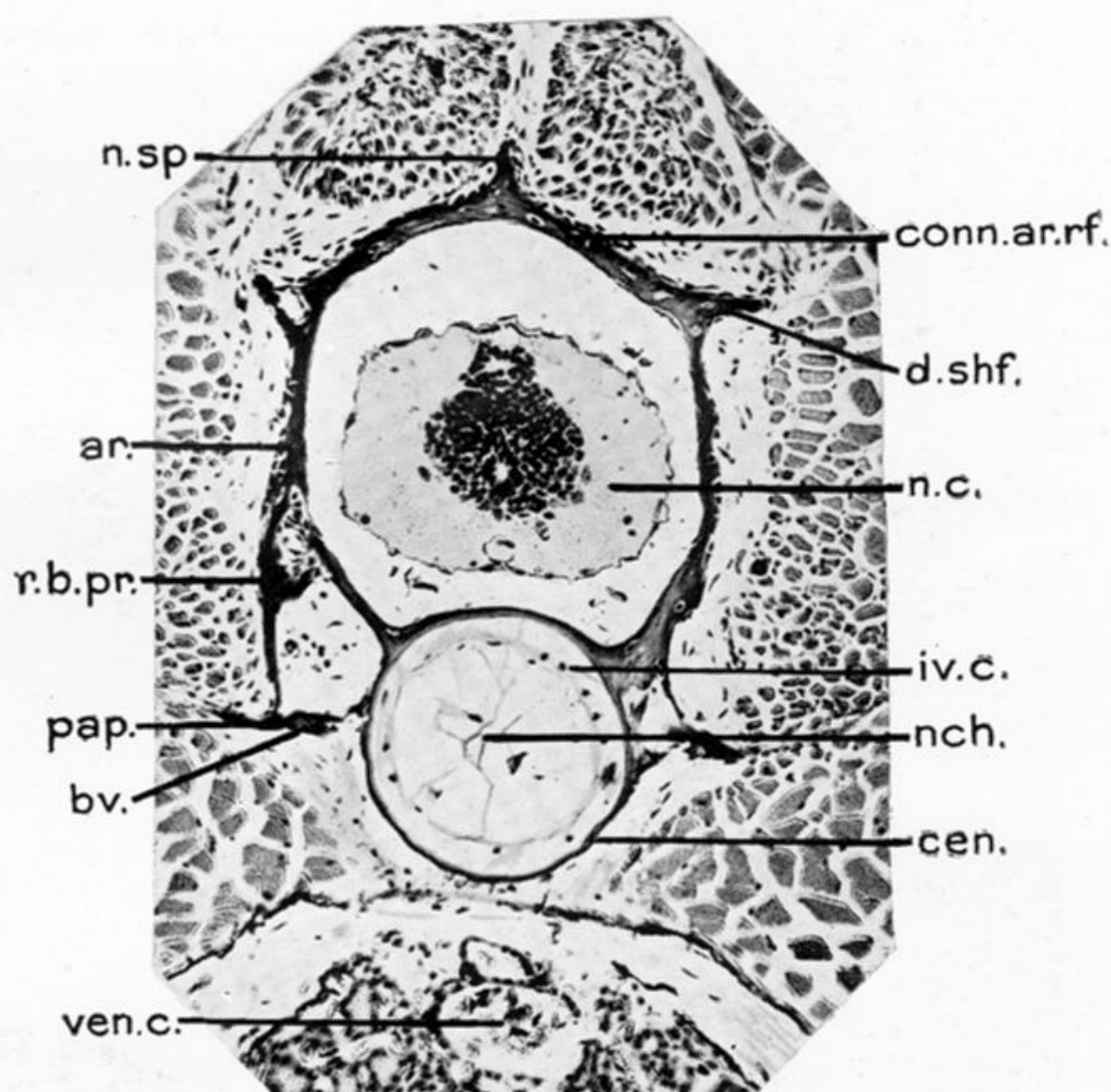
14.



15.

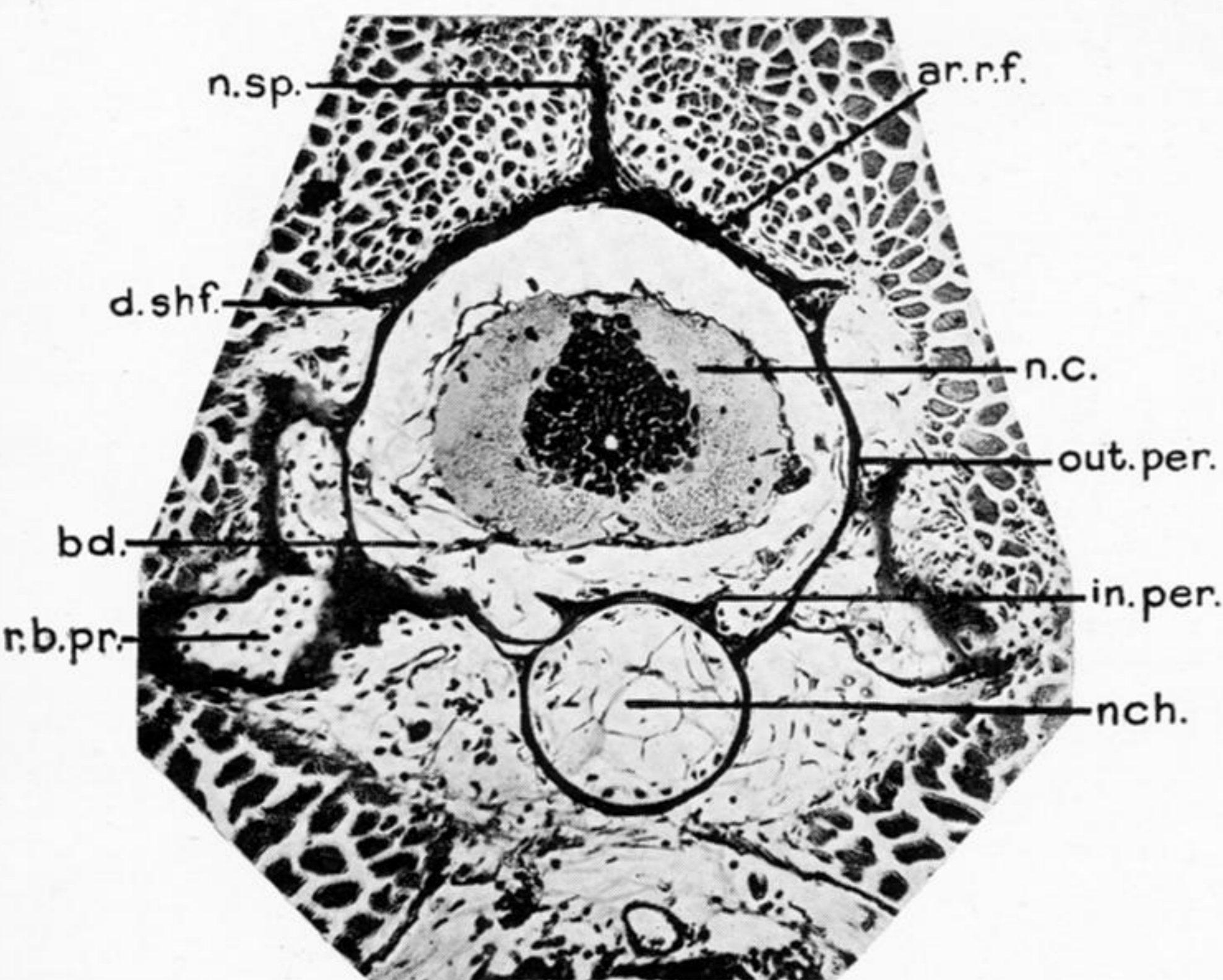


16.

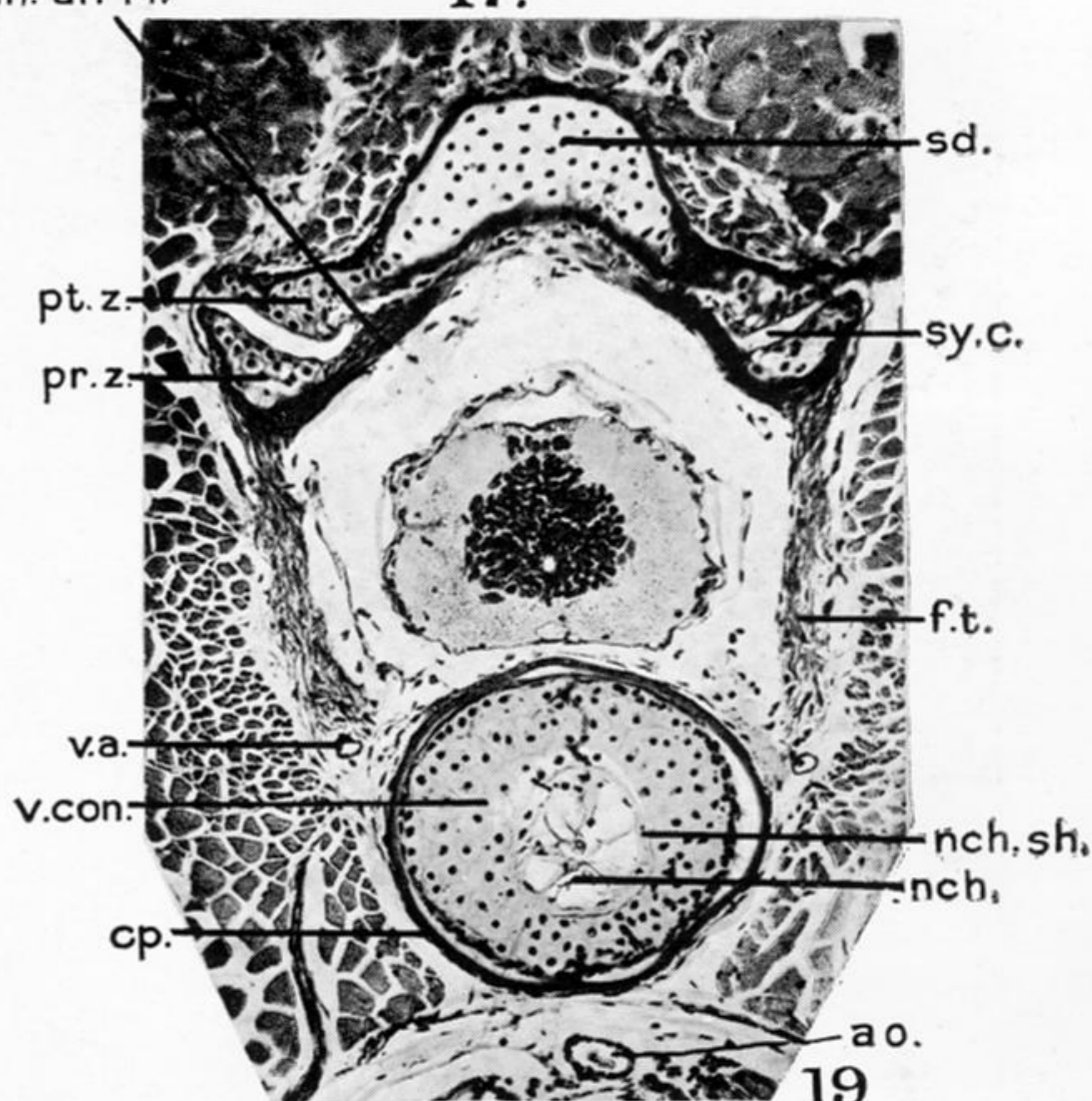


17.

conn. ar. rf.



18.



19

PLATE 46.

FIG. 14.—Transverse section through the trunk vertebra at 25 mm. stage. *ao.*, aorta; *bd.*, basidorsal; *conn.*, connective tissue forming roof of neural canal; *n.c.*, neural cord; *nch.*, notochord; *r.b.pr.*, rib bearing process.

FIG. 15.—Frontal section through the centra of a few vertebrae at 25 mm. stage. *conn.*, connective tissue which will form a synovial cavity; *bd.*, degenerating basidorsal; *iv.c.*, intervertebral cartilage; *nch.*, notochord; *r.*, rib; *r.b.pr.*, rib bearing process.

FIG. 16.—Transverse section through the beginning of a trunk vertebra at 35 mm. stage. *ao.*, aorta; *cen.*, centrum; *conn.ar.*, connective tissue arch; *conn.ar.rf.*, connective tissue arch roof; *itr.c.*, intravertebral cartilage; *nch.*, notochord; *n.c.*, neural cord; *nch.sh.*, notochordal sheath; *pr.z.*, pre-zygapophysis; *pt.z.*, post-zygapophysis; *v.a.*, vertebral artery.

FIG. 17.—Transverse section of the same stage a little posterior to the above. *bv.*, basiventral; *cen.*, centrum; *conn.ar.*, connective tissue arch; *conn.ar.rf.*, connective tissue arch roof; *iv.c.*, intervertebral cartilage; *n.c.*, neural cord; *nch.*, notochord; *n.sp.*, neural spine; *pap.*, parapophysis; *r.b.pr.*, rib bearing process.

FIG. 18.—Transverse section of the same, further posterior to the above. *bd.*, basidorsal; *conn.ar.rf.*, connective tissue arch roof; *d.shf.*, dorsal shelf; *in.per.*, inner perichondrium in course of dissolution; *out.per.*, outer perichondrium of basidorsal which ossifies; *r.b.pr.*, rib bearing process.

FIG. 19.—Transverse section through the same vertebra at the extreme posterior end. *ao.*, aorta; *conn.ar.rf.*, roof of connective tissue arch; *cp.*, cup of the vertebra behind; *f.t.*, fibrous tissue; *nch.*, notochord; *nch.sh.*, notochordal sheath; *pr.z.*, pre-zygapophysis; *pt.z.*, post-zygapophysis; *sd.*, supradorsal; *sy.c.*, synovial cavity; *v.a.*, vertebral artery; *v.con.*, condyle of the vertebra behind.

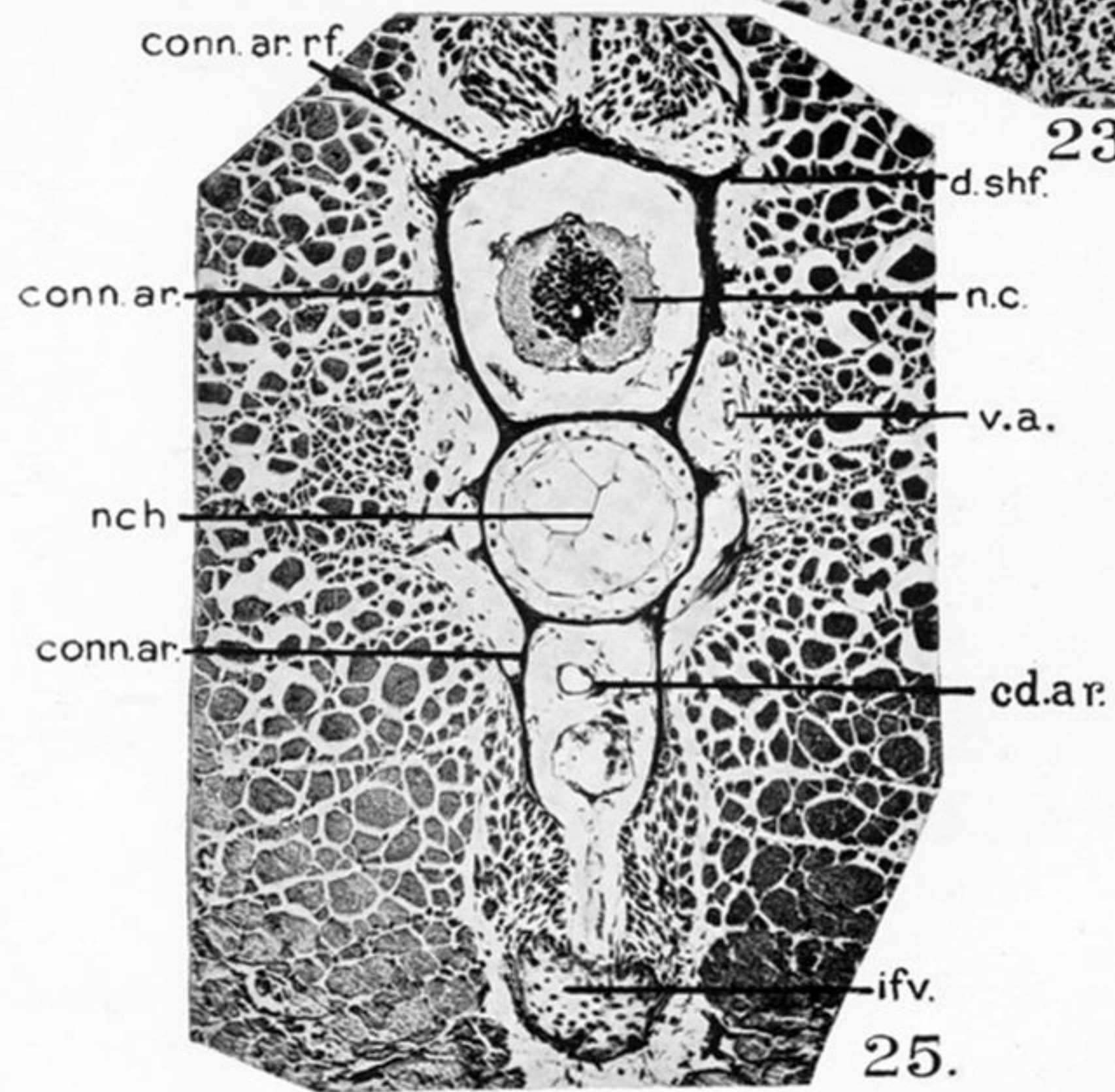
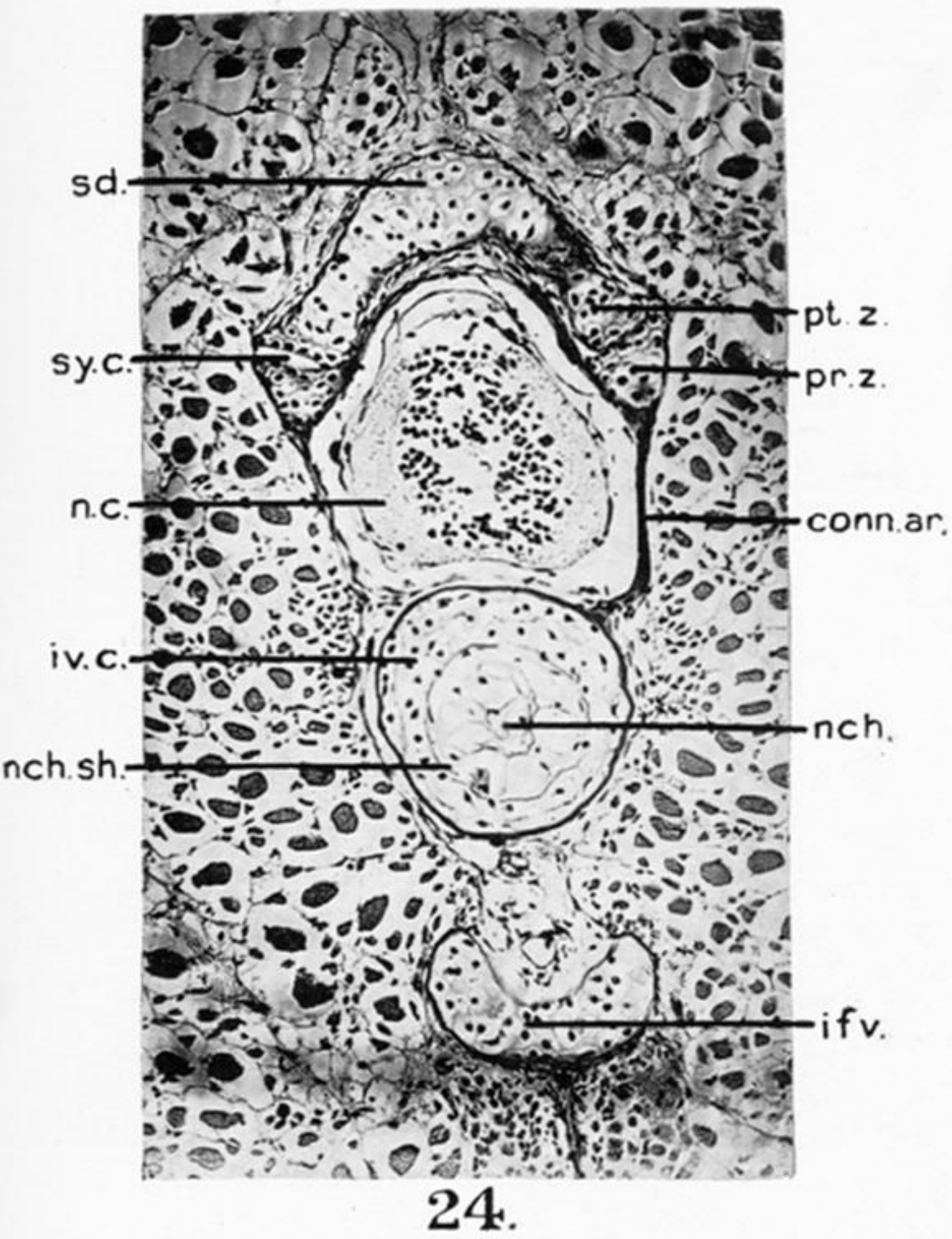
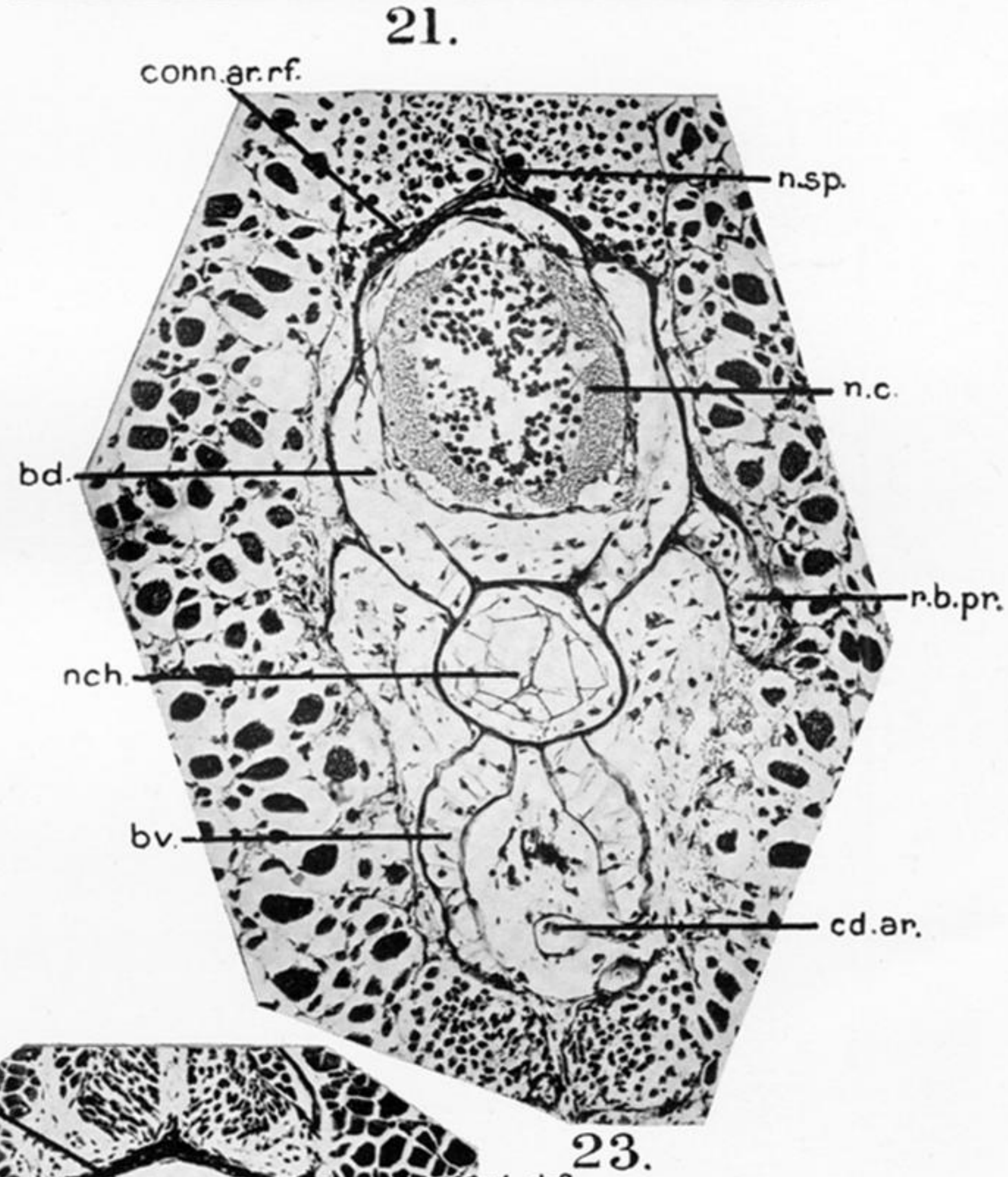
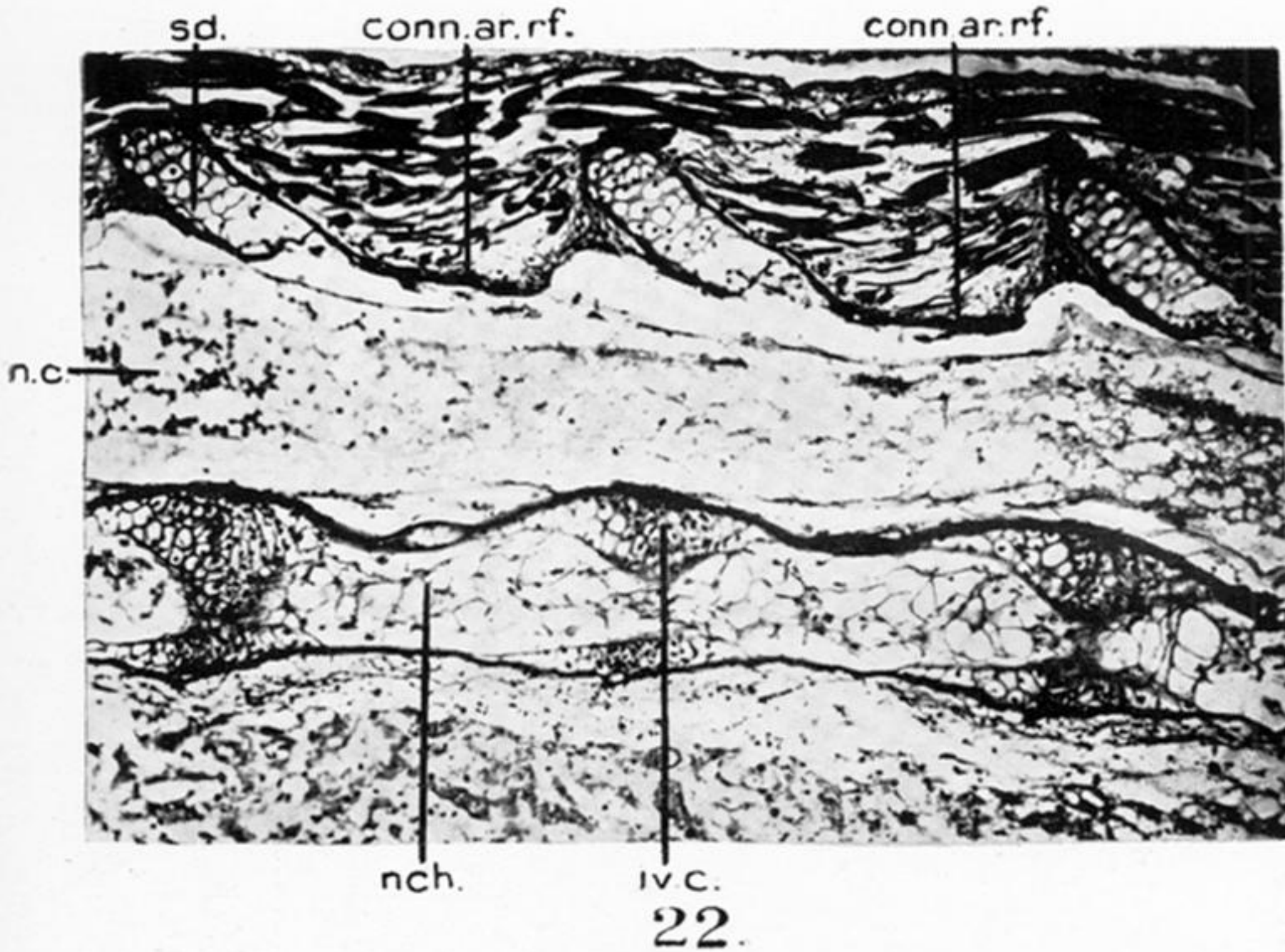
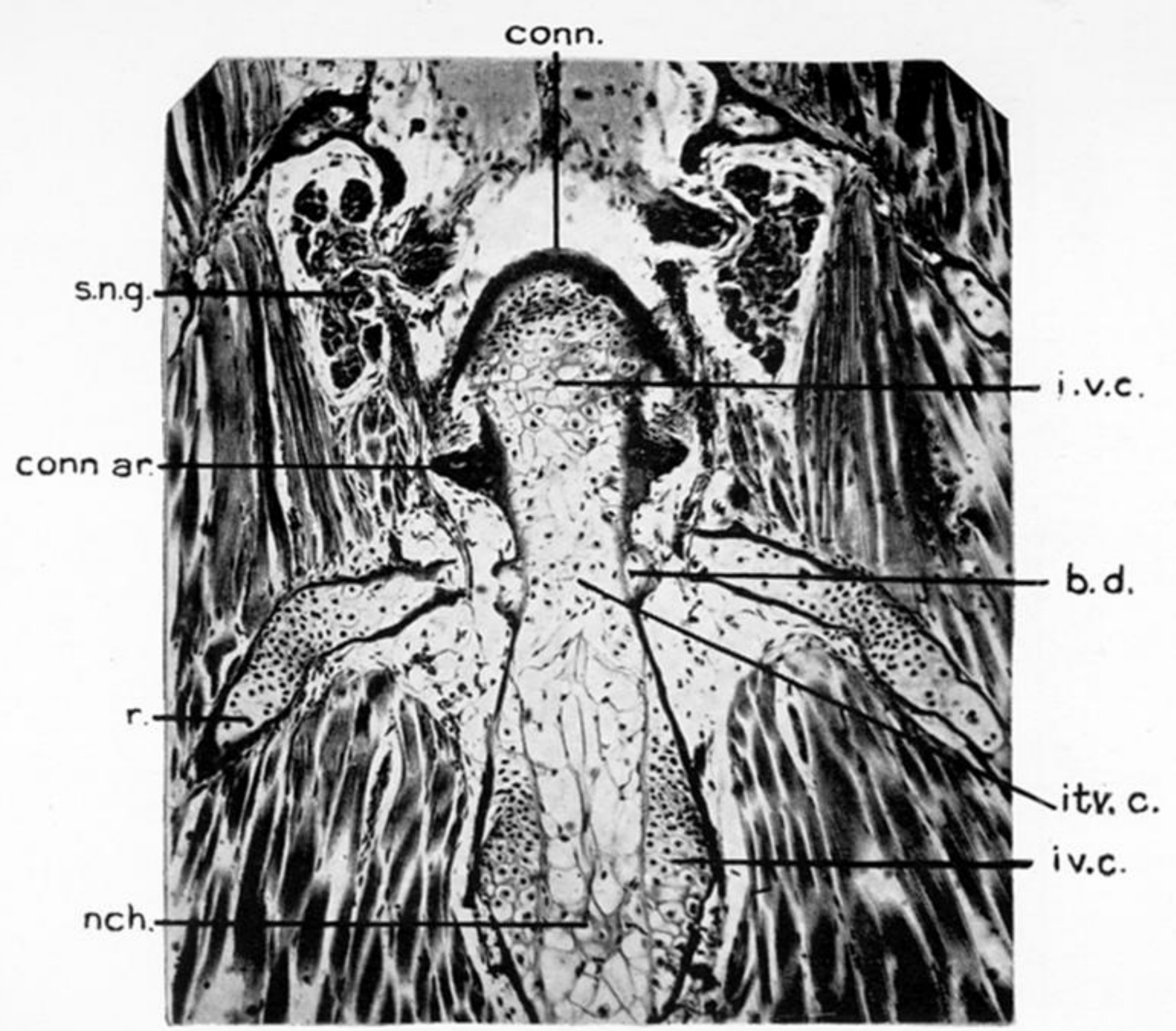
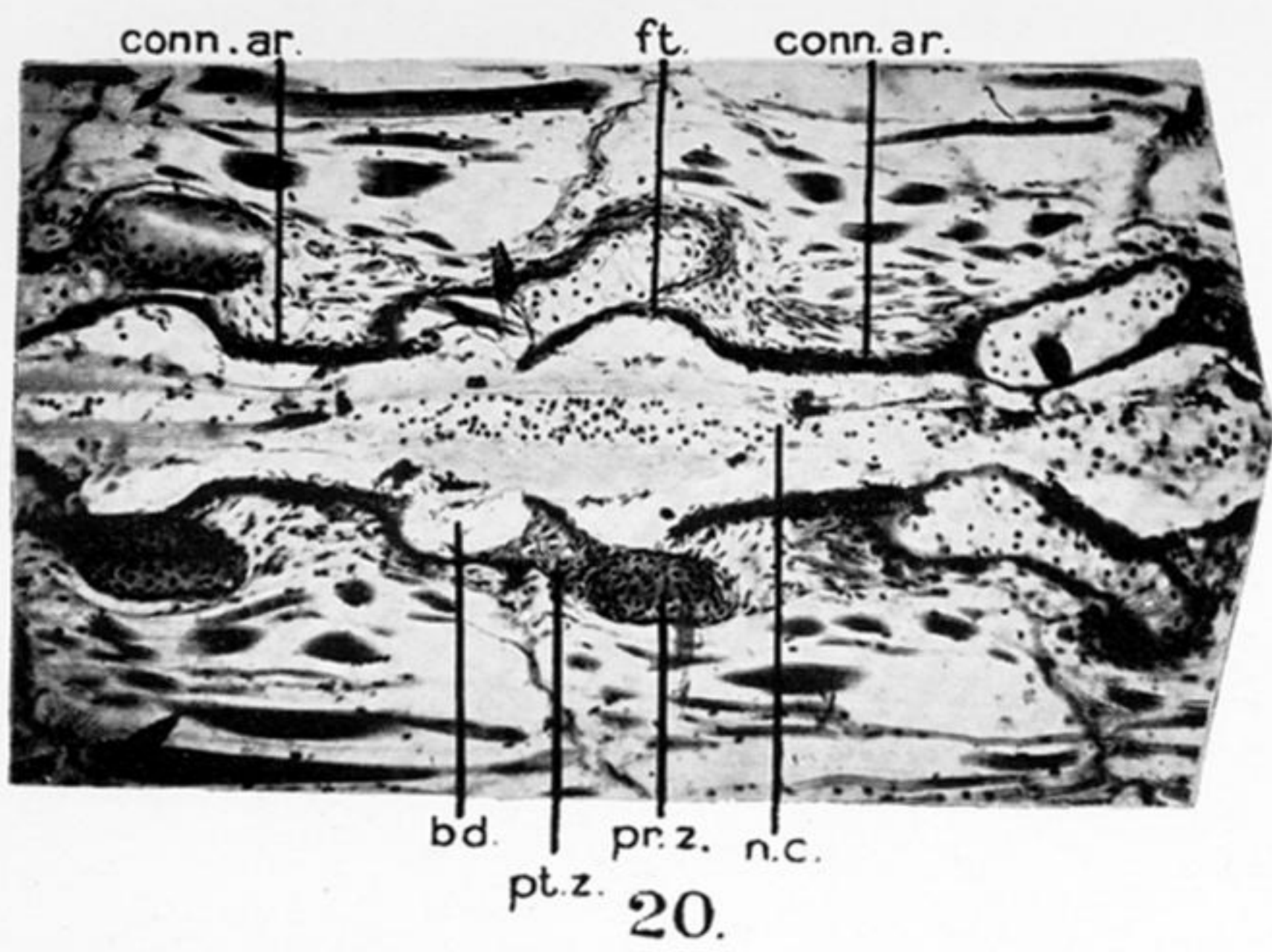


PLATE 47.

FIG. 20.—Frontal section through the dorsal portion of the neural arches at 35 mm. stage. *bd.*, basidorsal; *conn.ar.*, connective tissue arch; *ft.*, fibrous tissue; *n.c.*, neural cord; *pr.z.*, pre-zygapophysis; *pt.z.*, post-zygapophysis.


FIG. 21.—Frontal section through the centrum at 35 mm. stage. *bd.*, basidorsal; *conn.*, connective tissue forming the synovial cavity; *conn.ar.*, connective tissue arch; *itv.c.*, intravertebral cartilage; *iv.c.*, intervertebral cartilage; *nch.*, notochord; *r.*, rib; *s.n.g.*, spinal nerve ganglion.

FIG. 22.—Sagittal section through the middle of a few trunk vertebrae at 35 mm. stage. *conn.ar.rf.*, connective tissue arch roof; *iv.c.*, intervertebral cartilage; *n.c.*, neural cord; *nch.*, notochord; *sd.*, supradorsal.

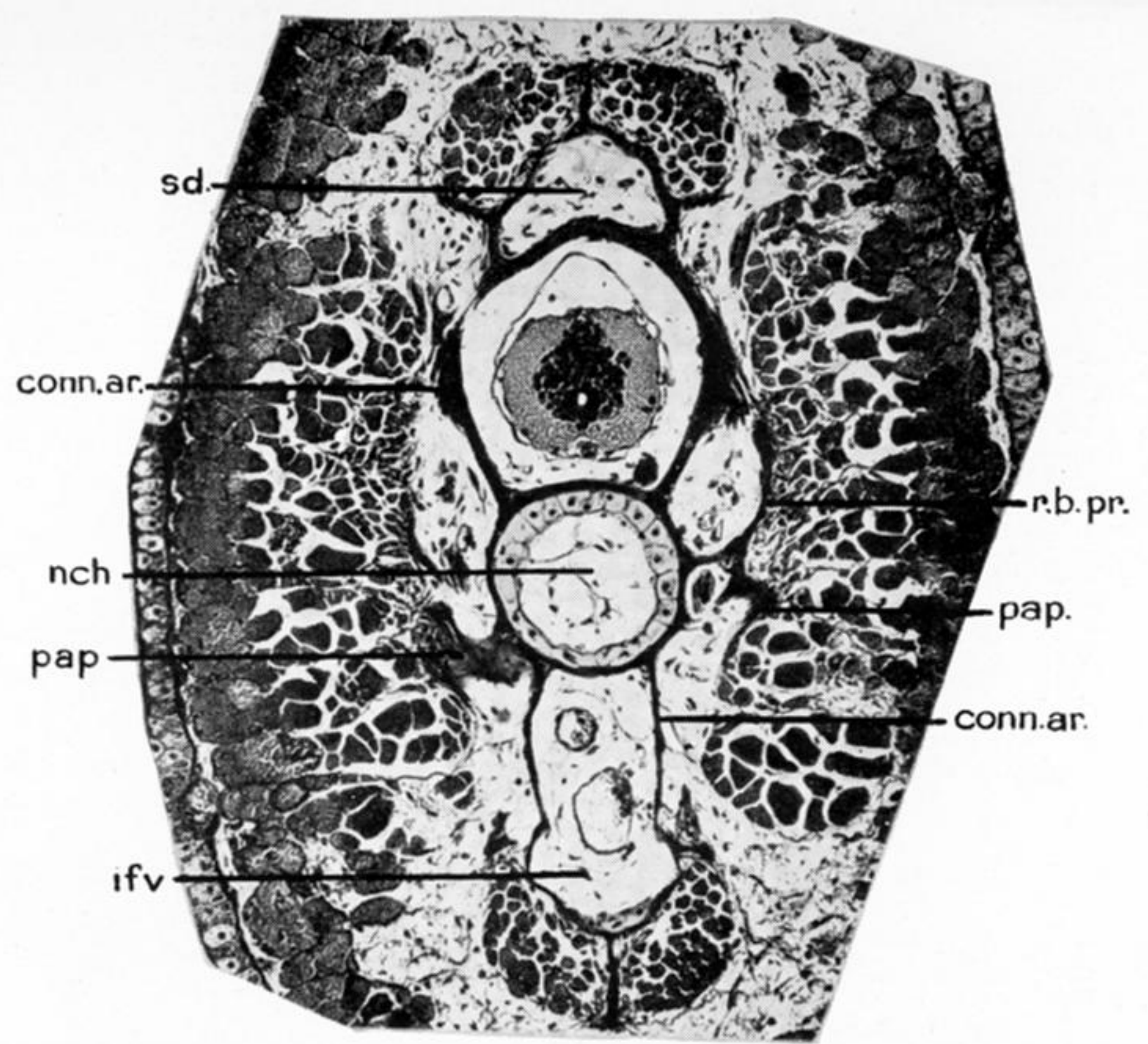
FIG. 23.—Transverse section through the middle of an anterior tail vertebra at 35 mm. stage. *cd.ar.*, caudal artery; *conn.ar.rf.*, connective tissue arch roof; *n.c.*, neural cord; *n.sp.*, neural spine; *nch.*, notochord; *r.b.pr.*, rib bearing process.

FIG. 24.—Transverse section through the posterior region of a tail vertebra at 35 mm. stage. *conn.ar.*, connective tissue arch; *ifv.*, infraventral; *iv.c.*, interventral cartilage; *nch.*, notochord; *n.c.*, neural cord; *nch.sh.*, notochordal sheath; *pr.z.*, pre-zygapophysis; *pt.z.*, post-zygapophysis; *sd.*, supradorsal; *sy.c.*, synovial cavity.

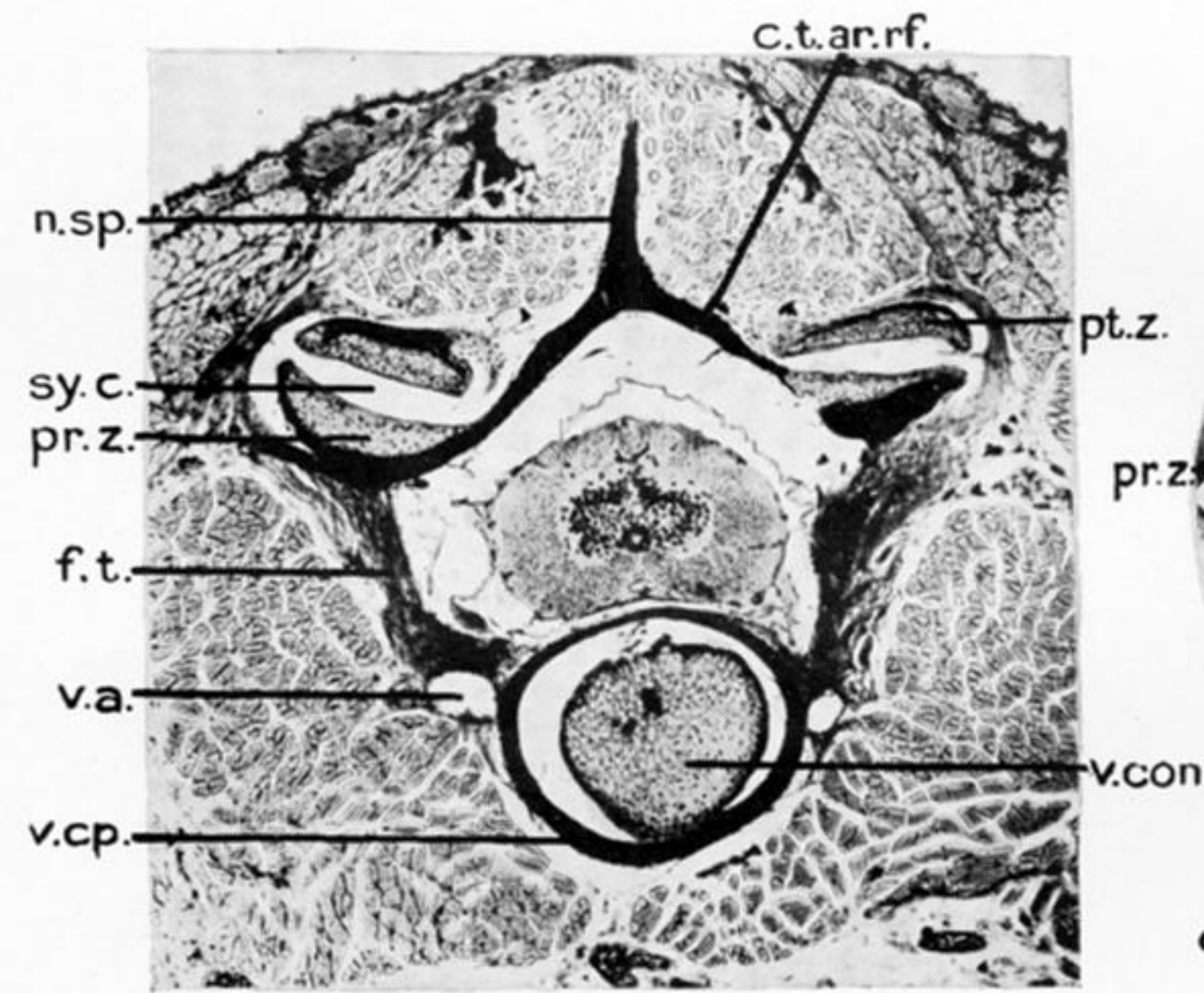
FIG. 25.—Transverse section through the tail in the region of the connective tissue arch at 40 mm. stage. *cd.ar.*, caudal artery; *conn.ar.*, connective tissue arch; *conn.ar.rf.*, connective tissue arch roof; *d.shf.*, dorsal shelf; *ifv.*, infraventral; *nch.*, notochord; *n.c.*, neural cord.



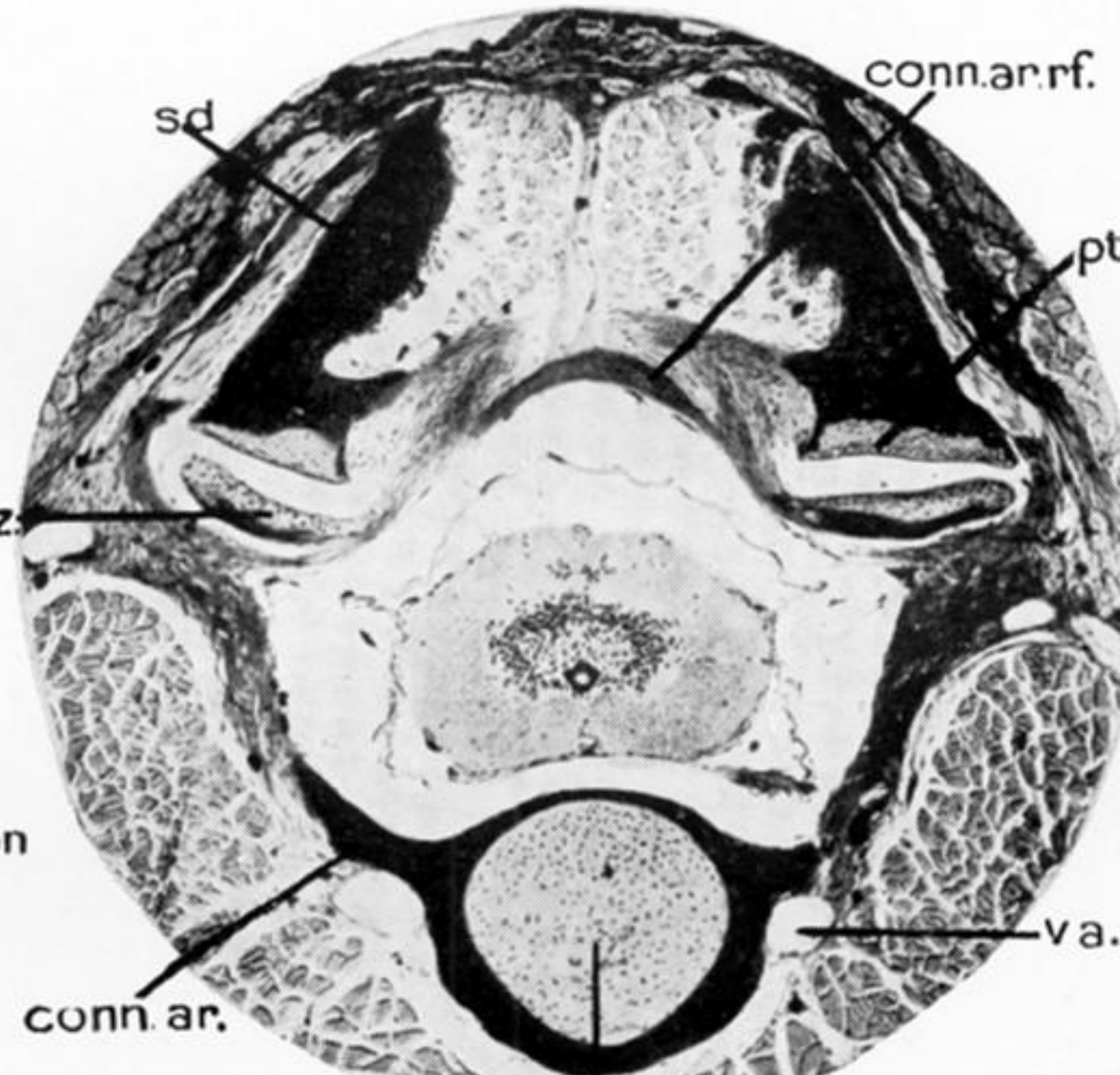
26.



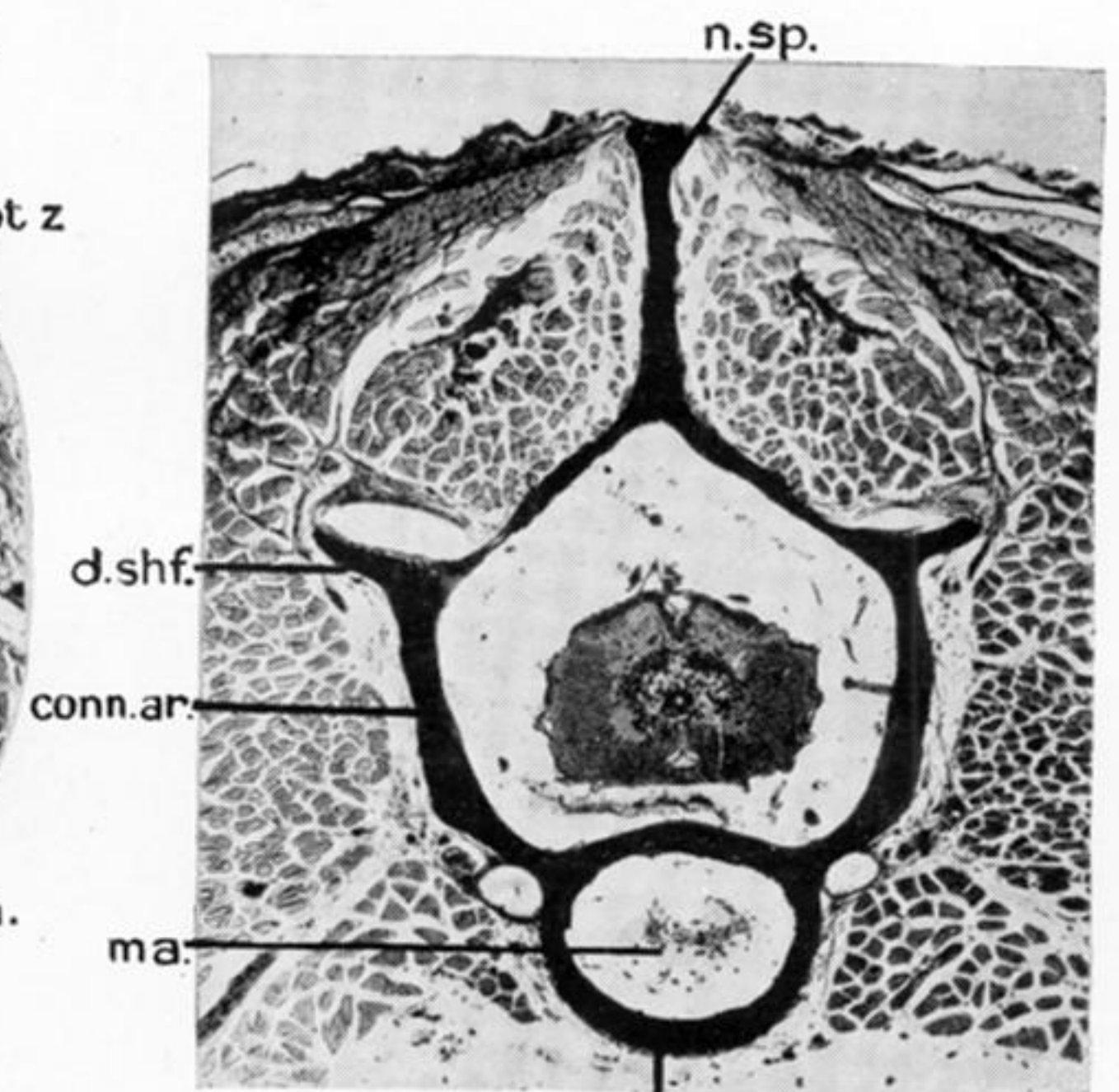
27.



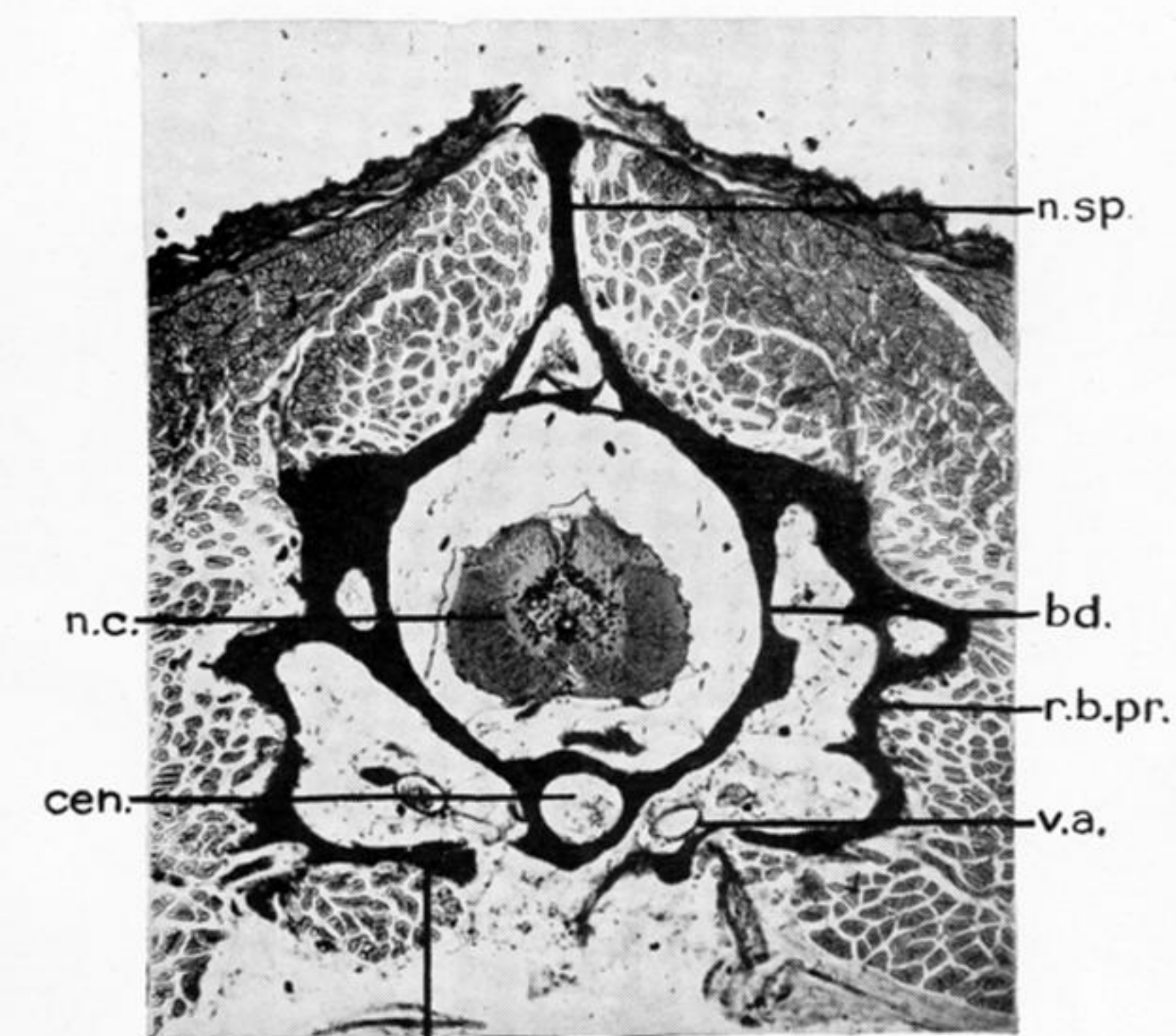
28.



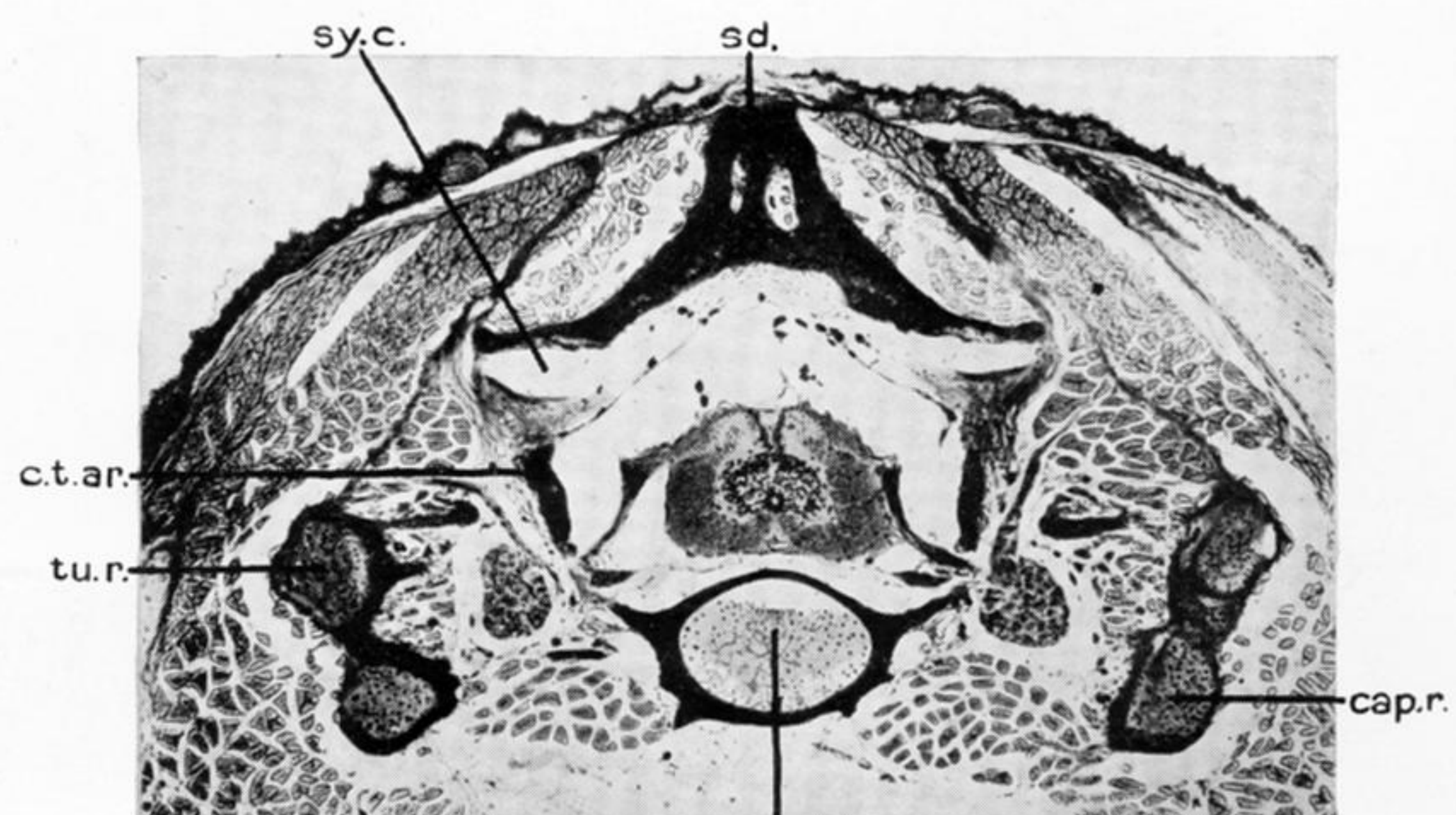
32.



29.



30.



31.

PLATE 48.

FIG. 26.—Sagittal section through the middle of a few tail vertebrae at 40 mm. stage. *conn.ar.rf.*, connective tissue arch roof; *f.t.*, fibrous tissue; *ifv.*, infraventral; *nch.*, notochord; *n.c.*, neural cord.

FIG. 27.—Transverse section through a tail vertebra at 40 mm. stage. *conn.ar.*, connective tissue arch; *ifv.*, infraventral; *nch.*, notochord; *pap.*, parapophysis; *r.b.pr.*, rib bearing process; *sd.*, supradorsal.

FIG. 28.—Transverse section through the beginning of a trunk vertebra at 65 mm. stage. *conn.ar.rf.*, connective tissue arch roof; *f.t.*, fibrous tissue; *n.sp.*, neural spine; *pr.z.*, pre-zygapophysis; *pt.z.*, post-zygapophysis; *sy.c.*, synovial cavity; *v.a.*, vertebral artery; *v.con.*, vertebral condyle; *v.cp.*, vertebral cup.

FIG. 29.—Transverse section through the same vertebra a little posterior to the previous figure. *cen.*, centrum; *conn.ar.*, connective tissue arch; *d.shf.*, dorsal shelf; *ma.*, marrow; *n.sp.*, neural spine.

FIG. 30.—Transverse section through the same vertebra further back. *bd.*, basidorsal; *cen.*, centrum; *n.c.*, neural cord; *n.sp.*, neural spine; *pap.*, parapophysis (*i.e.*, the true capitulum); *r.b.pr.*, rib bearing process; *v.a.*, vertebral artery.

FIG. 31.—Transverse section through the end of the same vertebra. *cap.r.*, capitulum of the rib; *conn.ar.*, connective tissue arch; *iv.c.*, intervertebral cartilage; *sd.*, supradorsal; *sy.c.*, synovial cavity; *tu.r.*, tuberculum of the rib.

FIG. 32.—Transverse section through the same vertebra at the extreme end of it. *conn.ar.*, connective tissue arch; *conn.ar.rf.*, connective tissue arch roof; *pr.z.*, pre-zygapophysis; *pt.z.*, post-zygapophysis; *sd.*, supradorsal; *v.a.*, vertebral artery; *v.con.*, vertebral condyle.